

Microinfusion of drugs into the skin with tattoo equipment

Microinfusão de medicamentos na pele através de máquina de tatuagem

Authors:

Samir Arbache¹
Carlos Eduardo de Godoy²

- ¹ Dermatology Service Assistant, Universidade de Mogi das Cruzes (UMC)—São Paulo (SP), Brazil
² Anatomopathologist Physician, Laboratório de Anatomia Patológica CIPAX—São José dos Campos (SP), Brazil

Correspondence:

Dr. Samir Arbache
R. Coronel Madeira, 45
Cep: 12245-760—São José dos Campos (SP), Brazil
E-mail: samir@dermocentro.com.br

Received on: 10 January 2013
Approved on: 20 February 2013

The present study was carried out at a private practice—São José dos Campos (SP), Brazil.

Financial support: None
Conflict of interest: None

ABSTRACT

A tattoo results from the introduction of pigments into the skin or mucous membranes. Pigments are chemical substances that behave like optical markers. Their visibility (through epithelial transparency) is undeniable proof that cutaneous perfusion with micro-perforations is an effective procedure. This method was used to infuse Bleomycin sulfate in two patients bearing keloid lesions, employing the same equipment and components used by professional tattoo artists, with adaptations for dermatological use, and strictly observing aseptic and rational requirements.

Keywords: surgical equipment; therapeutics; keloid; bleomycin.

RESUMO

Tatuagem é o resultado da introdução de pigmentos na pele ou em mucosas. Pigmentos são substâncias químicas que se comportam como marcadores ópticos. Sua visualização por transparência epitelial é prova incontestável de que a perfusão cutânea através de microperfurações é procedimento eficaz.

Escolheu-se esse método para infundir sulfato de bleomicina em duas pacientes portadoras de lesões queloidianas utilizando os equipamentos e consumíveis empregados por tatuadores profissionais, com adaptações para uso dermatológico de forma asséptica e racional.

Palavras-chave: equipamento cirúrgico; terapêutica; quelóide, bleomicina.

INTRODUCTION

The epidermis is mainly constituted of the corneum layer and keratinocytes strata, and acts as the body's mechanical, biological, and physical defense. Due to these characteristics, it prevents a fast and uniform absorption of medicaments.

The introduction of active ingredients into the dermis is still challenging. Topical drugs have variable penetration. While the intralesional injection is an effective method, it has some drawbacks, such as: a) the application of the product is technical-dependent, with irregular distribution in the dermis, b) microdosing is difficult when treating large areas, c) it is difficult to standardize the amount and depth of the active ingredient's application, and d) it is difficult to inject into very superficial lesions.

Conducting research in an attempt to permeate the skin with active therapeutic ingredients, Shelley¹ developed a successful method in 1991, terming it bleopuncture. The procedure consisted of performing punctures with bleomycin into common warts.

In 2001, España et al.² published the article “Bleomycin in the Treatment of Keloids and Hypertrophic Scars by Multiple Needle Punctures”, citing promising clinical results using this perfusion technique.

In the same line of therapy, Farahnaz³ mentioned the term “tattooing”, referring to the act of perforating and infusing bleomycin in hypertrophic scars and keloids, with needles. He compared and concluded that the results of the group of patients who underwent “tattooing” with bleomycin were superior to those of the other—in which conventional intralesional infiltrations of corticosteroids combined with cryotherapy were carried out.

Sadeghinia⁴ also uses the term “tattooing” for the procedure of puncturing keloids with needles, followed by an application of a solution of 5-Fluorouracil (5-FU). He concludes that the group treated with 5-FU achieved results superior to those treated with intralesional corticosteroid.

Saray⁵ describes the application of bleomycin with the assistance of Dermojet® (Akra Dermojet, France), a device that infuses active ingredients into the skin through high pressure, obtaining good results in hypertrophic scars and keloids refractory to treatment with corticosteroids.

The procedure described in the present study – the microinfusion of medicaments in the skin (MMS) – was conceived and based on the cited papers,¹⁻⁵ to be administered by physicians through the ancient tattooing procedure. The mere existence of tattoos would be unequivocal evidence that it is possible to infuse pigments, which are optical markers of the absorption of chemicals through micro-orifices in the skin (Figure 1). In MMS, after acting in the tissues, the infused active ingredients would be probably absorbed and eliminated in a variable period of time.

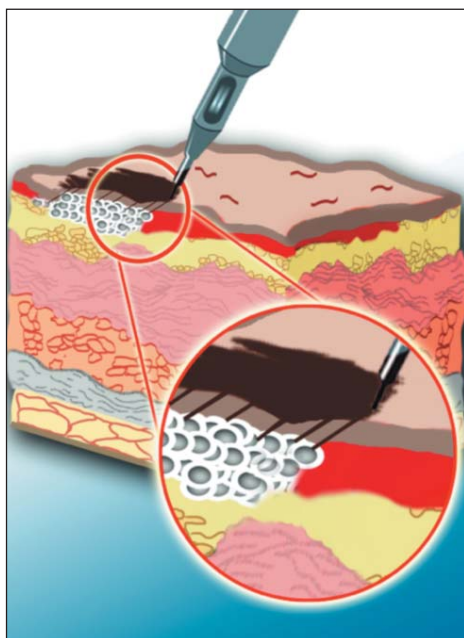


FIGURE 1: Artistic illustration of a tattoo demonstrating pigments inserted in the superficial dermis through microperforations

All of MMS' concepts (asepsis, knowledge of the pathophysiology of the condition being treated, and the infused active ingredients' pharmacology) are based on protocols consolidated and improved by tattoo practitioners for millennia.

METHODS

Tattoos are perhaps the most frequent, invasive skin procedure carried out worldwide. A tattoo requires the use of specific devices, which are generally unknown by dermatologists. Below are the descriptions of such devices:

1) Tattoo machine (body): patented by Samuel O'Reilly in 1891, it has a rudimentary function that resembles the rotation system of a sewing machine. Hundreds of models are available in Brazil (some certified by ANVISA – the Brazilian Health Surveillance Agency). The device, many times with adjustable speed operation, is powered by simple sources of energy.

2) Tips: there are autoclavable and disposable tips, which are available in sealed, sterile packages. The authors have chosen to use disposable tips due to their practicality and low cost. Most disposable tips are registered with ANVISA (Figure 2).

3) Needles: needles are relatively cheap, and are also available in sealed, sterile packages. They comprise a variable set of very fine diameter microneedles arranged linearly or circularly. Gently piercing the skin, they provide very fast healing, analogous to that of the tattoos. Most needles available in Brazil are registered with ANVISA (Figure 3).

The needles, when assembled together at the tip, form a handset that is perfect for handling. The infusion's depth can be adjusted from 0.1 to 2.0mm, depending on the epidermis' thickness and the condition to be treated (Figure 4). The design of the distal end of the tip is also ingenious, for the medicament to be infused remains stored in a container above the application end of the tip (Figure 5). The appearance of the area treated with the micro-needling process resembles that of very delicate fractioning (Figure 6).

The authors chose to evaluate the MMS' efficacy through the treatment of keloid lesions with bleomycin sulfate, which is considered effective in the intralesional treatment of scars and keloids. Toxic effects are uncommon.⁶

Bleomycin sulfate is an antineoplastic agent that inhibits the synthesis of collagen by fibroblasts. It is considered affordable, safe in the intralesional treatment of keloids and hypertrophic scars, and devoid of unusual systemic drug effects.⁶ Bleomycin is made available in its lyophilized form with recons-



FIGURE 2: Disposable tip




FIGURE 3: Left: needles in sterile packages; Center: microneedles arranged linearly; Right: microneedles arranged circularly



FIGURE 4: Application end of the tip—the depth of the treatment is adjustable




FIGURE 5: Note the ingenious medicine storage above the application end of the tip. The red arrow indicates the level of the liquid medicine.

titution being carried out so that each milliliter contains 1.5 units of the active ingredient.

CLINICAL CASES

1) A female patient had had presternal keloid for four years. The etiology was probably related to traumatized acne comedonica. The lesion was divided into three segments: bleomycin was infused on the left side, no treatment was applied to the central section, and 0.9% saline solution was infused on the right side. Two infusions were administered at 30-day intervals. The thickness of the treated areas was clinically homogeneous (Figure 7).

2) A female patient had had a linear pubic keloid for two years, secondary to a cesarean section. The thickness was clinically irregular. The lesion was divided into two segments: bleomycin was infused in the right side and 0.9% saline on the left side. Only one infusion was performed (Figure 8).

The infusions were performed by a single dermatologist physician, following subcutaneous infiltration of 2% lidocaine.

The tattoo machines, tips, and needles used in the procedure were approved by ANVISA. The patients returned several times for clinical evaluations and photographic documentation, with the development of the treated lesions being followed up by one applicator dermatologist physician and one observer dermatologist physician. The patients and the physicians were aware that each keloid segment had received different treatments, however they were blind to the nature of the infused active ingredient. Both the dermatologists and the patients observed visually and through palpation that the two lesions infused improved in thickness—with the area infused with bleomycin presenting a more significant reduction. They have also observed that the consistency of the area infused with bleomycin was reduced.

Four weeks after the last infusion, biopsies of the treated areas, which reached the subcutaneous fat, were taken using the punch method. The reduction in the thickness of the keloid areas infused with bleomycin, as compared with those infused with saline solution, was proven microscopically (Table 1). The

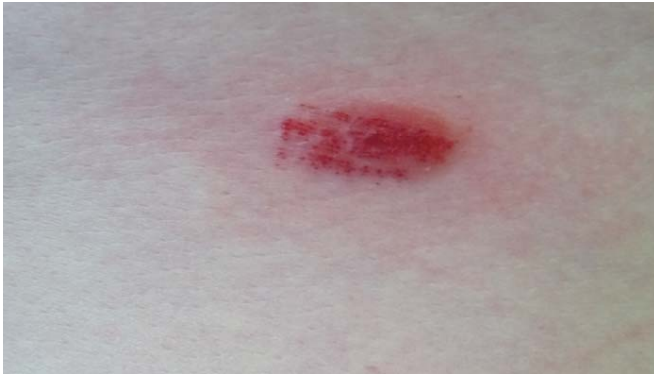

FIGURE 6: Appearance of an erythematous lesion that underwent micro-perforation with the needles.

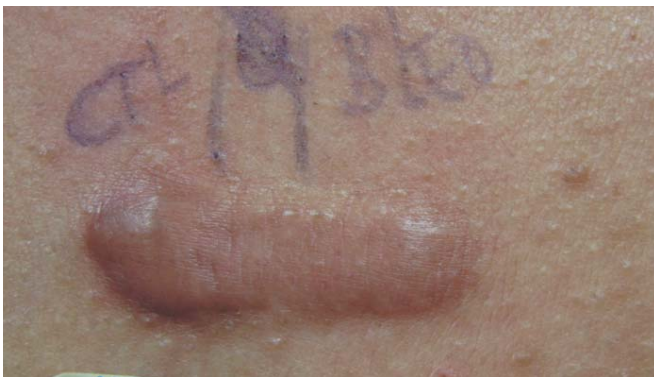

FIGURE 7: Appearance of a keloid lesion after two infusion sessions with saline solution and bleomycin; also note the reduction in the thickness and hyperpigmentation of the treated areas.

histological analysis, initially performed to accurately measure and compare the thickness of the treated areas, revealed a decreased density of collagen fibers and interstitium with myxoid appearance, only in the areas infused with bleomycin. Also, a reduced number of fibroblasts and decreased lymphocytic inflammatory infiltrate could be noted (Figure 9 and 10). The measure of the depth of those microscopic alterations evidenced that they had not reached the entire thickness of the fibrosis (Table 2).

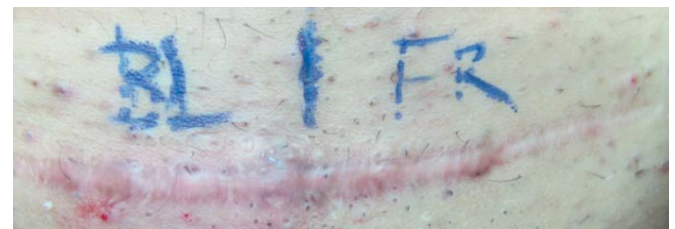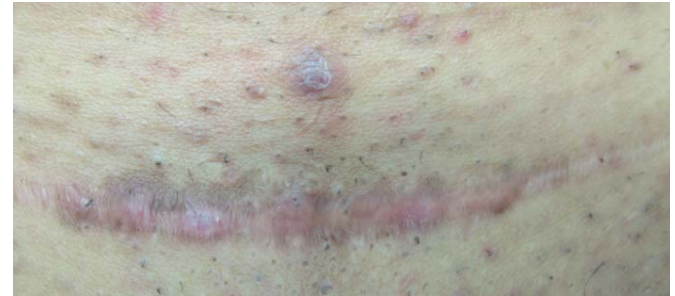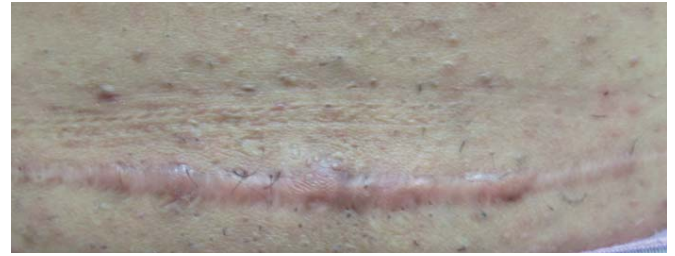


FIGURE 8: Appearance of the lesion before (above) and after (below) the infusion session with saline solution and bleomycin.

DISCUSSION

The reduction in the thickness of the keloid scars in this study was clinically and histologically visible, having been more clearly demonstrated in the areas infused with bleomycin. Tissular alterations observed in the areas infused with bleomycin demonstrated that the drug was actually infused and absorbed by the dermis. The reproduction of results in other keloids will mean an innovation in the use of an already known non-medical equipment, however adapted for medical treatment. Infusion of drugs with a therapeutic end will witness the addition of a new weapon to the therapeutic armamentarium of dermatologists. Keloids are a frequent cutaneous deformity that causes physical defects and psychological disorders. There is no permanent cure, but treatments are available for improving the picture. The adaptation of an inexpensive device increases the possibility of intervention by dermatologists in this disfiguring condition. The use of this non-medical device for infusing drugs may become useful in the treatment of scars and superficial keloids, or in the case of keloids resistant to conventional treatments, provided that physicians indicate the medicine and apply their clinical, anatomo-pathological, and pharmacological therapeutic knowledge for the therapeutic intervention.

The complete set of equipment used to perform the MMS (i.e. the machine, tips, needles, etc.) has been developed for years, implying that no investment was needed in order to design and develop a new medical device. The consumables and

TABLE 1: Lesions' thicknesses after the last infusion session with bleomycin and saline solution

Infusion type Keloid thickness	Case 1		Case 2	
	Bleomycin	Saline solution	Bleomycin	Saline solution
	3,8mm	4mm	3mm	4mm

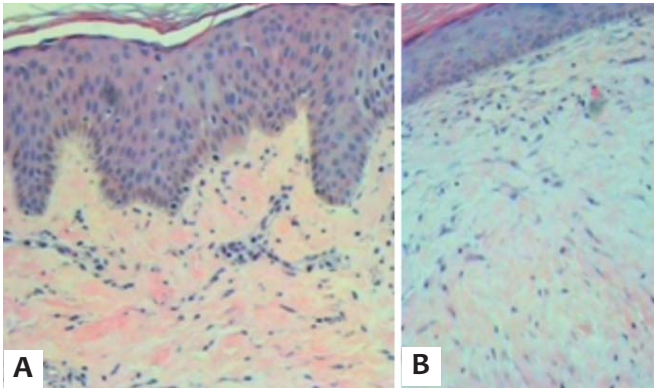


FIGURE 9: **A.** HE—Area infused with saline solution—dense collagen fibers, numerous intermingled fibroblasts and sparse mononuclear inflammatory infiltrate can be noted. **B.** HE—Area infused with bleomycin—loose collagen fibers with myxoid stroma, lower density of fibroblasts and discrete mononuclear inflammatory infiltrate.

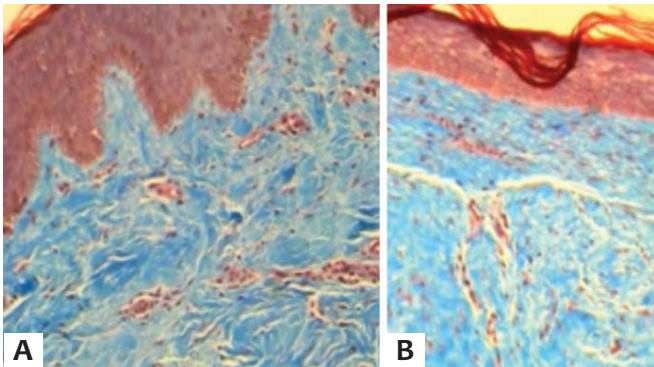


Figure 10: **A.** Masson's Trichrome—area infused with saline solution: dense collagen fibers (blue), compacted and disposed orderly. **B.** Masson's Trichrome—area infused with bleomycin: loose collagen fibers.

machines, which are inexpensive, have been developed during the last century by lay technicians.

Other methods, such as fractional lasers, fractional radio frequency, and some micro-needling devices (roller and pen), can be used for the infusion of medications.⁷ These methods do not have the MMS' functionality, efficiency, and asepsis. The great delicacy of the perforation process combined with the possibility of using it on small spot lesions, makes MMS unmatched to date. Fractional lasers, in addition to having a considerably high cost, when perforating the skin cause a thermal effect on the perforations' walls, hindering the absorption of the drug. Because it has a thermal effect on the perforations' walls, frac-

TABELA 2: Profundidades das alterações histológicas observadas nas cicatrizes queiloideanas

	Case 1	Case 2
Profundidade das alterações histológicas	2,5mm	2mm

tional radio-frequency requires the combined use of ultrasound aimed at increasing the perfusion of the drug.

CONCLUSION

MMS is a procedure that precisely, effectively, and cost effectively delivers active ingredients into the skin. Because it has a low cost of implementation, it presents a horizon of therapeutic alternatives to the dermatologist. Further studies are necessary to technically improve the procedure, the choice of drugs to be infused and their concentrations, quantification of absorbed substances, and the possibility of skin sensitization. ●

Acknowledgements: The authors would like to thank the Dermatology Department of the Universidade de Mogi das Cruzes (UMC)—São Paulo (SP), Brazil.

REFERENCES

- Shelley WB, Shelley ED. Intralesional Bleomycin Sulfate Therapy for Warts. *Arch Dermatol.* 1991;127(2):234-6.
- España A, Solano T, Quintanilla E. Bleomycin in the treatment of Keloids and Hypertrophic Scars by Multiple Needles Punctures. *Dermatol Surg.* 2001;27(1):23-7.
- Naeini FF, Najafian J, Ahmadvpour K. Bleomycin Tattooing as a Promising Therapeutic Modality in Large Keloids and Hypertrophic Scars. *Dermatol Surg.* 2006;32(8):1023-30.
- Sadeghinia A, Sadeghinia S. Comparison of the Efficacy of Intralesional Triamcinolone Acetonide and 5-Fluorouracil Tattooing of the Treatments of Keloids. *Dermatol Surg.* 2012;38(1):104-9.
- Saray Y, Güleç AT. Treatment of keloids and hypertrophic scars with dermojet injections of bleomycin: a preliminary study. *Int J Dermatol.* 2005;44(9): 777-84.
- Leventhal D, Furr M, Reiter D. Treatment of Keloids and Hypertrophic Scars. A Meta-analysis and Review of the Literature. *Arch Facial Plast Surg.* 2006;8(6):362-8.
- Kassuga L, Issa M, Chevrand N. Aplicação transepidérmica de medicamento associado a terapia fotodinâmica no tratamento de ceratoses actínicas. *Surg Cosmet Dermatol.* 2012;4(1):89-92.