

Review Article

Authors:

Sandra Tagliolatto¹
Vanessa Barcellos Medeiros²
Oriete Gerin Leite³

¹ MSc, Surgical and Clinical Dermatology Department, Universidade Federal de São Paulo (Unifesp) – Campinas (SP), Brazil

² Dermatologist Physician, Campinas

³ Dermatologist Physician, Campinas

Correspondence:

Dra. Sandra Tagliolatto
R. Luzitana, 740, 4º andar – Bosque
Cep: 13015-121 - Campinas – SP, Brazil
E-mail: dermoclinica@dermoclinica.med.br

Received on: 5 April 2012
Approved on: 2 May 2012

This study was carried out at the authors' private practices in Campinas (SP), Brazil.

Conflict of interest: None
Financial support: None

Laserlipolysis: update and literature review

Laserlipólise: atualização e revisão da literatura

ABSTRACT

Laser lipolysis is a therapeutic modality that is currently used to treat localized fat and promote cutaneous retraction. Compared to conventional liposuction, removing fat using laser lipolysis has a shorter post-operative recovery time and fewer adverse effects. Applying laser directly to adipose tissue causes fat liquefaction, blood vessel coagulation and collagen denaturation. The thermal damage induces neocollagenesis and skin contraction. The technique's safety is well documented. This study reviews the literature on laser lipolysis and describes its current status.

Keywords: lasers; lipolysis; subcutaneous fat; collagen.

RESUMO

A laserlipólise é modalidade terapêutica utilizada atualmente no tratamento da gordura localizada e retração cutânea. Demonstra vantagens na remoção da gordura em relação à lipoaspiração convencional, com menor tempo de recuperação pós-operatória e menores efeitos adversos. A aplicação do laser diretamente no tecido adiposo promove liquefação da gordura, coagulação de vasos sanguíneos e desnaturação do colágeno. O dano térmico induz neocolagênese e contração da pele. A segurança da técnica é bem documentada. Este estudo propõe-se a revisar a literatura sobre laserlipólise, assim como apresentar o estado atual dessa tecnologia.

Palavras-chave: lasers; lipólise; gordura subcutânea; colágeno.

INTRODUCTION

The laser lipolysis technique has been used for over a decade to treat localized fat to promote skin tightening and to reshape the body's contour. It is one of the more frequently used procedures in the United States in liposculpture, which is performed by roughly 10% of plastic surgeons.^{1,2}

Laser lipolysis comprises the subcutaneous application of laser under tumescent anesthesia in the treated area of the body, with or without the subsequent aspiration of molten fat. When in direct contact with the subcutaneous tissue, the energy relea-

sed by the laser inflicts irreversible damage on the adipocytes, in addition to thermal damage to the dermal collagen fibers, stimulating neocollagenesis and, later, a skin-tightening effect.³

Advantages over traditional liposuction, such as shorter recovery time, milder surgical trauma, decreased blood loss, as well as less pain, bruising, and post-surgical swelling, have been demonstrated. The improvement in elasticity and retraction of the skin promoted by laser lipolysis have made this technique an interesting alternative for defining the body's contour.⁴ Like tumescent liposuction, laser lipolysis can be performed in an outpatient setting, yielding high rates of patient satisfaction and low rates of complications.⁵

This article reviews the updated literature on laser lipolysis, describing the different wavelengths and lasers used, and their practical applications and results.

LIPOSUCTION AND PRECURSORS

The introduction of tumescent liposuction in the 1990s resulted in lower rates of complications than traditional liposuction, which is carried out under general anesthesia. Additional advantages included a reduced risk of bleeding and ecchymosis and faster post-operative recovery, without the need for hospitalization.⁶

Tumescent anesthesia, as described by Klein,⁷ is a buffered solution containing 500-1,000 mg lidocaine, 1mg epinephrine, and 12.5 ml of 8.4% sodium bicarbonate in one liter of saline solution. The presence of epinephrine, as well as the great volume injected, promotes local vasoconstriction and decreases intra-operative blood loss.⁸

Tierney and colleagues published a review article about the safety of tumescent anesthesia in liposuction and laser lipolysis in 100,000 treated areas of the body. There were no systemic complications, and the risk of local complications was very low.⁹

In 1992, Zocchi introduced ultrasound in tumescent liposuction. Ultrasound was applied prior to aspiration in order to emulsify the fat. An enhanced technique of that approach, the VASER (Vibration Amplification of Sound Energy at Resonance), allowed a greater emulsification of fat with less applied energy.⁴

However, side effects such as large seromas and damage to peripheral nerves discouraged the use of this technique. Ultrasound-assisted liposuction or low-potency lasers used externally showed no evidence of better results, and had restricted applications.^{4,10}

LASER LIPOLYSIS: FIRST REPORTS IN THE LITERATURE

Between 1992 and 1996, Apfelberg published the first studies on laser lipolysis using the neodymium yttrium aluminum garnet laser (Nd:YAG) inside the liposuction cannula.¹¹ At first there was no evidence that this approach was superior to tumescent liposuction.⁸

In 2002, Goldman and others described their experience with more than 1,700 patients, demonstrating the effects of thermal energy released by laser lipolysis using a 1,064 nm

Nd:YAG pulsed laser. That laser uses a 300 um-thick optical fiber contained within a 1 mm microcannula. Unlike in the work of Apfelberg, the optical fiber was extended about 2 mm at the distal end of the cannula so that it could be in direct contact with the adipose tissue and small blood vessels. The authors were the pioneers in demonstrating the effects on adipose tissue, adjacent dermis, vasculature, and eccrine and apocrine glands.³

At the same time, Badin and colleagues studied the histological alterations caused by the laser, finding ruptures in the membranes of adipocytes, coagulated blood vessels, and denatured collagen fibers in reorganization. Those findings were similar to the clinical response (removal of localized fat, less intraoperative bleeding, less ecchymosis, in addition to obtaining the skin-tightening effect).¹²

In October 2006, based on a more robust scientific basis, the US Food and Drug Administration approved the use of the first laser (1,064 nm Nd:YAG) for performing laser lipolysis, incision, excision, vaporization, ablation, and coagulation in soft tissues. Several studies have been published since then, contributing to a greater understanding of the technique and the technological advancements.

LASER LIPOLYSIS PRINCIPLES

Laser lipolysis' mechanism of action is based on the classic principle of selective photothermolysis. The internal system of controlled energy aims to reach two chromophores: fat and collagen. The direct exposure of the target tissue to the laser results in selective thermolipolysis and the thermal denaturation of collagen fibers, which maintains the septal architecture and contributes to the increase in cutaneous retraction.¹³

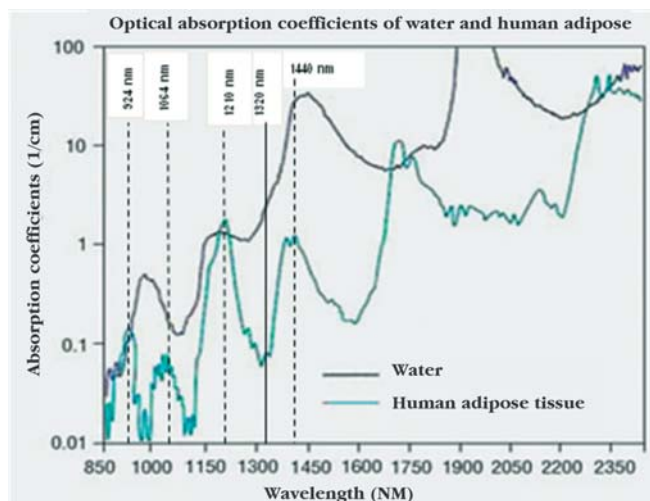
Subcutaneous tissue fat has an optical absorption coefficient estimated between 400 and 1,500 nm. Collagen's optical absorption coefficient is similar to that of water and thus increases in direct proportion to the wavelength.¹⁴ Graph 1 depicts the curves of optical absorption of human fat and water (collagen); the coefficients of absorption of fat and water peak at different wavelengths.

The thermal factor is the main cause of adipocytolysis and contraction of the skin. The fat (liquefied due to the rise in temperature of the adipocytes) depends on the total energy accumulated in the treated area.^{14,15} Therefore, given that the result of the lipolysis and stimulation of collagen depends on the amount of thermal energy accumulated in the tissue, some studies suggest monitoring the temperature during laser lipolysis.¹⁶

The external temperature must remain between 40°C and 42°C not only for greater effectiveness, but also to prevent burns. The internal temperature must reach 48-50°C in order to cause irreversible adipocytolysis and denaturation of the adjacent collagen, with the resulting stimulation of neocollagenesis.¹⁸

Histological studies have confirmed the clinical benefits resulting from the laser's action in the skin, including the destruction of adipocytes, the remodeling of collagen, and the coagulation of blood and lymph vessels.^{3,16,17,19}

Tumescent adipocytes were observed with the use of low-



Graph 1: Optical absorption curves of fat and water. The vertical lines indicate the wavelengths in which peaks of fat absorption occur. At the 1,320 nm wavelength there is greater selectivity for collagen

energy laser, whereas the use of high-energy laser led to cytoplasmic retraction, membrane destruction, and coagulation of collagen and blood fibers. Even higher levels of energy produced fat tissue carbonization involving fibers and membranes.^{20,21}

Several types of laser and different wavelengths have been used in laser lipolysis. Photoacoustic, photothermal, and photo-mechanical effects are theoretical mechanisms of action typical of the method.⁵

Regardless of the wavelength used, however, the thermal damage caused by the heat seems to be responsible for the beneficial effects of the method.²⁰ In 2008, Mordon and colleagues described a mathematical model for laser lipolysis based on 980 nm diode laser and 1,064 nm Nd:YAG. The studies suggest that the heat level attained – which depends on the accumulated energy – is more important than the wavelength used for reducing fat and promoting the retraction of the skin.¹⁸

THE TECHNIQUE

Laser lipolysis is an outpatient procedure performed without the need for hospitalization. Laboratorial investigation, with complete blood count, laboratory tests for clotting and liver function, electrolytes, beta-HCG for women of childbearing age, and serology for hepatitis B, C, and HIV must be requested.⁵

Pictures and marking of the treatment areas must be carried out with the patient in standing position. The tumescent local anesthesia is administered through a 1-2 mm incision, in an outpatient surgical room. A 1 mm microcannula containing the laser optical fiber is then inserted into the subcutaneous plane, and is moved back and forth, parallel to the surface, at an average speed of 5 cm/s, 10-15 times in each area.⁴

A light emitted by the laser in the hand piece's tip guides the execution of the procedure through the skin's transparency

(Figure 1). During the procedure, one hand moves the cannula while the other is placed on the treated surfaces in order to immobilize the tissue, to gauge the local temperature, and to pinch the skin in order to assess the softening of the subcutaneous layer.

After the use of the laser, the liquefied fat is usually aspirated with a small-diameter cannula using negative pressure. In some cases, only manual drainage is performed. In the treatment of sagging, aspiration is not necessary.

Antibiotics and analgesics are prescribed, and patients are instructed to use compression bands specific to each treated area for 15-30 days, and to avoid exposure to the sun for a month. Physical activity should be avoided for one week, and complementary physiotherapy sessions are recommended. The patients must be followed up in the first and third months after treatment to evaluate the results.

WAVELENGTHS

The development of lasers with other wavelengths suggests the existence of more specific lengths for targeting fat and collagen chromophores, although this is still scientifically unproven. The various types of lasers used in laser lipolysis are shown in Table 1.

There is no consensus, however, regarding the best and most specific wavelength for laser lipolysis, since the fat and collagen absorption coefficients vary greatly regarding that parameter, as already seen. In recent years, lasers with two or three combined wavelengths have been developed in an attempt to optimize results.

In 2010, Wassmer and colleagues compared lasers with different wavelengths (920 nm, 980 nm, 1,064 nm, 1,320 nm, and

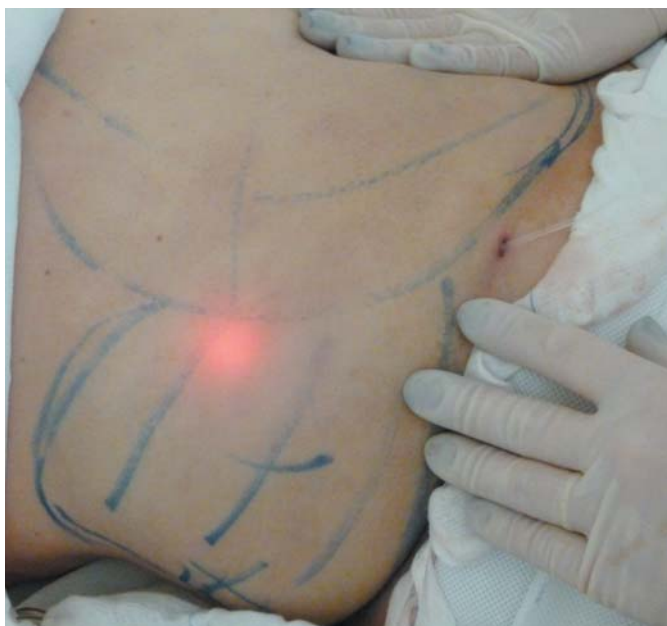

Figure 1: Laser lipolysis in the lateral abdominal region. Note the light emitted by the laser handpiece's tip serving as a guide in the site of application

1,440 nm) and concluded that the tissular penetration was similar among those with wavelengths between 900 nm and 1,320 nm (approximately 1.5 mm). The volume of fat destroyed was similar at wavelengths of 920 nm and 1,320 nm. For every 4 cm³ of molten fat, the average accumulated energy used was 3,750 J.¹⁴

Tark and others presented superior lipolytic results in the skin of pigs with 1,444 nm Nd:YAG laser, compared to those obtained with 1,064 nm. 22 Weiss and Beasley studied the effects of two laser wavelengths (924 nm for fat, 975 nm for collagen) in 19 patients, obtaining 100% good and excellent results. 23 Reszko and others concluded that the 1,320 nm Nd:YAG laser caused greater dermal coagulation compared to the 1,064 nm laser.¹

DiBernardo and colleagues evaluated and compared the effects of 1,064 nm and 1,320 nm lasers (combined and in isolation) on localized fat and dermal collagen, concluding that the histological damage was correlated with the temperature reached, regardless of the wavelength. The authors suggest that external temperatures higher than 42°C are linked to undesirable epidermal damage.¹⁶

In a similar study, Woodhall and others compared the effects of 1,064nm and 1,320nm Nd:YAG lasers in isolation and combined; the latter showed superior clinical results.²⁴

INDICATIONS AND APPLICATIONS

The main indications for laser lipolysis are the removal of localized fat that is resistant to physical exercise and diets, and the correction of mild to moderate sagging. The treatment's goal is to improve the definition of the body's contour. In the literature, there are recent reports of other applications of laser lipolysis, such as the treatment of lipomas, axillary hyperhidrosis, gynecomastia, facial sagging, and cellulite.

Patients who are in the normal range of body mass index have the ideal profile for treatment. They must be well informed about the technique and the time required to obtain the expected results, which generally occurs three months after the procedure.¹² Those patients should preferably be less than 60 years

of age, and not have uncontrolled cardiovascular disease, hypertension, diabetes, or a liver condition. Anticoagulants, anti-inflammatory drugs, or medications that alter the metabolism of lidocaine are contraindicated.⁵

LOCALIZED FAT AND MILD TO MODERATE SAGGING

The treatment of localized fat to improve the definition of the body's contour is the first indication of laser lipolysis – similar to that of tumescent liposuction. The regions most frequently treated using this technique are the abdomen, waist, outer thighs, submentonian and submandibular regions, inner thighs, knees, arms, and back.

Some studies have measured the skin retraction associated with the use of laser, which has led to a fast expansion of this technique in the United States.^{15,25} The experience amassed in recent years has yielded further information about optimizing the parameters used, as well as the degree of improvement that can be achieved.

Reynaud and colleagues have calculated the average accumulated energy per region of application of 980 nm diode laser, after analyzing 534 procedures.²⁶ Table 2 shows the mean values, as well as the minimum and maximum values applied to each body region, as a guideline for the surgeon.

Figures 2 and 3 demonstrate three cases of patients who were treated for fat and sagging with 924/975 nm diode laser-based laser lipolysis.

OTHER INDICATIONS

Gynecomastia

The first study reporting laser lipolysis as an option in the treatment of gynecomastia was published in 2002 by Goldman and colleagues.³ The authors found that laser lipolysis presented more efficacy in more fibrous areas – as is the case with traditional liposuction in gynecomastia.

In 2009, Rho and others applied 1,064 nm Nd:YAG laser in five patients with unilateral gynecomastia and compared the results with the untreated side. The applied accumulated energy ranged from 1,800–2,500 J. There was a reduction in chest cir-

Table 1 – Lasers used in the United States for laser lipolysis

Laser	System	Wavelength	Year of approval by FDA*
SmartLipo: Cynosure	Nd:YAG	1064 nm	2006
SmartLipo MPX: Cynosure	Nd:YAG	1064/1320 nm	2008
SmartLipo Triplex: Cynosure	Nd:YAG	1064/1320/1440 nm	2009
CoolLipo: CoolTouch	Nd:YAG	1320 nm	2007
LipoLite: Syneron	Nd:YAG	1064 nm	2008
Lipotherm: Osyris	Diodo	980 nm	2008
SlimLipo: Palomar	Diodo	924/975 nm	2008
SmoothLipo: Eleme	Diodo	920 nm	2008
ProLipo: Sciton	Nd:YAG	1064/1319 nm	2009
AccuSculpt: Lutronic	Nd:YAG	1444 nm	2010

*FDA: Food and Drug Administration, EUA.

Table 2 – Average accumulated energy by area of the body

Region	Average accumulated energy (min-max)	
Abdomen	24.600 J	(6–51 kJ)
Outer thighs	14.600 J	(2,2-31 kJ)
Waist	9.500 J	(4-19 kJ)
Posterior face of the thighs	13.100 J	(4-25 kJ)
Inner thighs	10.400 J	(4-20 kJ)
Submandibular	11.700 J	(6,6-16 kJ)
Arms	12.800 J	(4,7-17 kJ)
Inner knees	8.100 J	(2,7-20 kJ)
Back	21.900 J	(11-35 kJ)

cumference in all cases eight weeks after the procedure. A decrease in the thickness of the fat and mammary tissue was detected by CT scans and ultrasound.²⁷

In 2012, Trelles and colleagues conducted a prospective study in 28 patients with gynecomastia, who underwent laser lipolysis with 980 nm diode laser with good results, including the skin-tightening effect.²⁸

Figure 4 shows the results of the treatment of a gynecomastia patient by the authors after subcutaneous application of 924/975 nm diode laser. The parameters used were 18/16 W fluence and 7,000 J of accumulated energy.

LIPOMAS

Lipomas are benign, yet large tumors that require excisional surgeries that result in unattractive scars. Laser lipolysis has been described in three recent articles in the literature as a treatment for large cutaneous lipomas. In 2009, Goldman and Wollina evaluated 20 patients who underwent laser lipolysis with 1,064nm Nd:YAG pulsed laser, followed by aspiration. All patients had the tumor removed, and there were four partial recurrences that required a repeat of the same procedure, with therapeutic success.²⁹

In 2010, Saluja described the use of laser with two wavelengths in the treatment of giant lipomas with a post-procedure scar of 1.5 mm.³⁰ Likewise, in 2011 Stebbins and others described two patients whose lipomas were successfully treated with laser lipolysis (the largest measuring 12 x 8 cm, located on the back).³¹

The authors describe a patient who underwent treatment for a large lipoma on the back, using laser lipolysis with 924 nm laser diode, 20 W fluence, and an accumulated energy of 15,000 J. Figure 5 illustrates the primary lesion and the final result one month after two laser applications.

AXILLARY HYPERHIDROSIS AND OSMIDROSIS

The number of reports describing laser lipolysis in the treatment of axillary hyperhidrosis or osmidrosis has been increasing in the last few years. In 2006, Ichikawa and colleagues

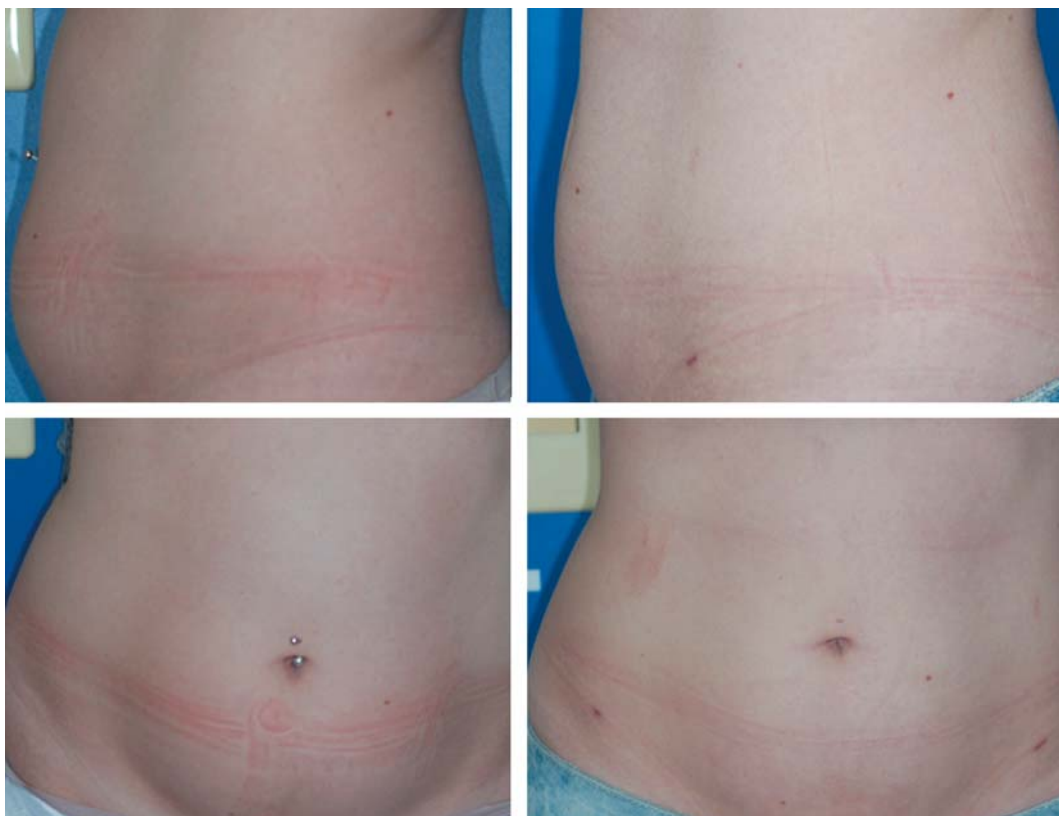

Figure 2: Before laser lipolysis + aspiration in the abdomen and waist with 924/975 nm diode laser (above: profile view, below: frontal view) and one month after the procedure (20W/20 W fluence, and 40,000 J of total accumulated energy)

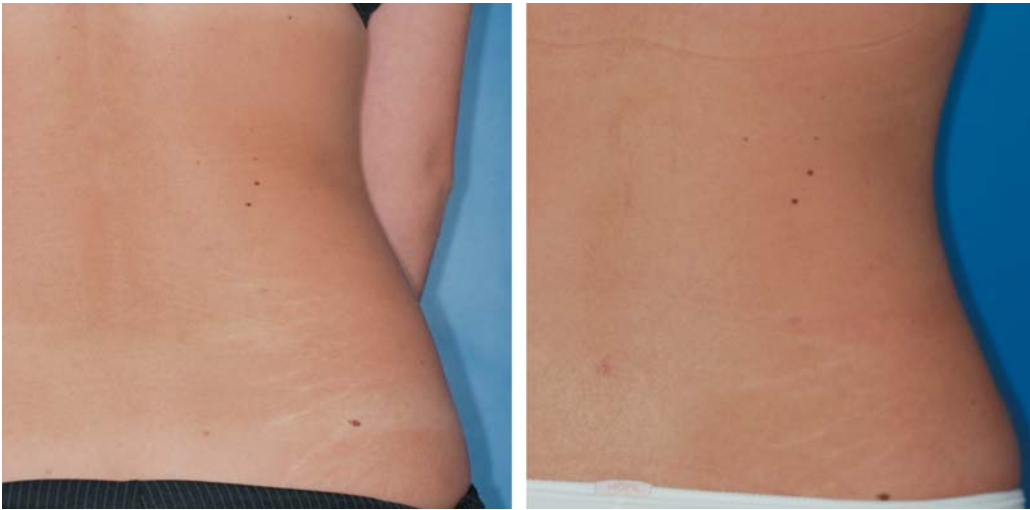

Figure 3: Before laser lipolysis + aspiration in the waist and three months after the procedure (924/975 nm diode laser, 20W/20 W fluence, and 30,000 J of total accumulated energy)

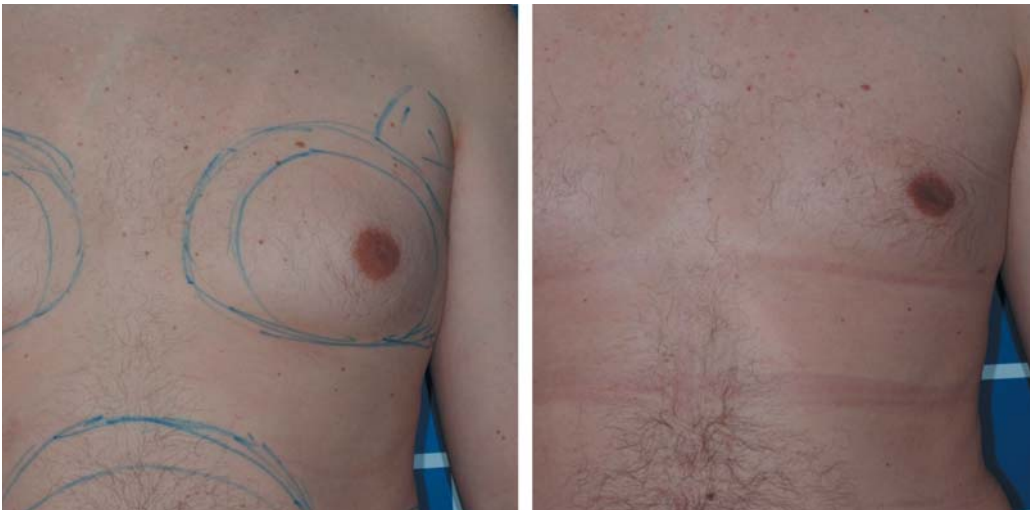

Figure 4: Before laser lipolysis + aspiration to treat gynecomastia and one month after the procedure

reported the subdermal use of 1,064 nm Nd:YAG laser in 17 osmidrosis cases for ablating sweat glands. Twelve patients were monitored six months after the procedure, with good to moderate responses in all cases. Treatment areas were divided into 2 cm squares, each of which received 200–300 J of accumulated energy.³²

In 2008, Goldman and Wollina described the clinical and histological outcomes of the application of subdermal 1,064 nm Nd:YAG laser in 17 patients with difficult-to-control hyperhidrosis. Treatment areas were established using Minor's iodine test and received 7,000–20,000 J of total accumulated energy. All patients presented a significant and lasting decrease of hyperhidrosis, with excellent outcomes in 10 patients. There was a recurrence of symptoms in only one patient five months after the procedure. Histology of biopsies performed after the procedure showed necrosis and collapse of the eccrine glands.³³

In 2011, Kotlus reported the case of a patient with hyper-resistant axillary hyperhidrosis who underwent subdermal

1,320 nm Nd:YAG laser. The improvement was considered satisfactory.³⁴

More recently, Kim and colleagues described the use of sub-dermal 1,064 nm Nd:YAG laser in osmidrosis (n = 29) with a 12-month clinical follow-up. Nineteen patients responded well, but 10 patients presented poor results. Each 2 cm square received 300–500 J of accumulated energy. There were also three cases of second-degree epidermal burns. The authors observed improvement only in milder cases of osmidrosis.³⁵

FACIAL CONTOUR AND SAGGING

In a review article on laser lipolysis, Sasaki and Tevez described its application in facial and body contour procedures, highlighting the effectiveness and safety of the technique using the 1.064/1.320 nm Nd:YAG laser.¹³

In Asia in 2009, Sun and others reported a case of congenital adiposity in the face of a 19-year-old female patient, who was treated with subdermal 1.064 nm Nd:YAG laser with a good

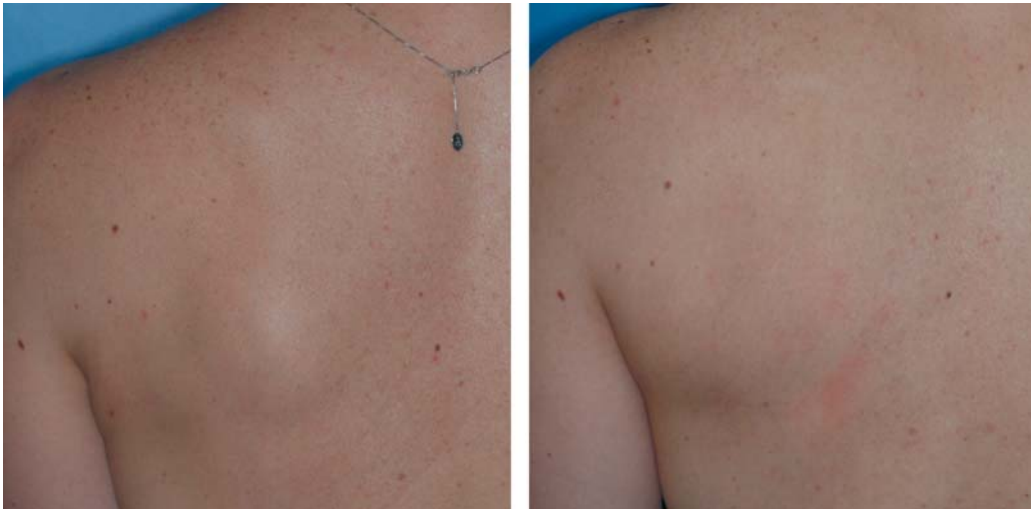

Figure 5: Before laserlipolysis + aspiration of scapular giant lipoma and after two sessions, illustrating the excellent aesthetic result and imperceptible scar six months after the procedure

outcome and an absence of damage in the peripheral nerves.³⁶

Holcomb and colleagues published a case study of 478 patients who underwent laser lipolysis for rejuvenation and to define the facial contour with 1,444 nm Nd:YAG laser. There were good results in the correction of the middle and inferior thirds of the facial contour.³⁷

Aiming to promote face lift based on the skin-tightening effect, in 2011 McMenamin obtained good outcomes with 1.064/1.319 nm and 1.064/1.320 nm Nd:YAG lasers in facial contour procedures in 40 patients.³⁸

CELLULITE

Gynoid lipodystrophy – or cellulite – is a common aesthetic disorder that is difficult to treat. It is characterized by the presence of fibrous bands in the adipose tissue and herniations of the fat lobes toward the dermis. Several surgeons have noted an improvement in cellulite after laser lipolysis.⁵

In 2008, Goldman and others reported positive effects of laser lipolysis combined with autologous fat transplant to treat

52 patients with Curri cellulite grades III and IV.⁶

In 2011, DiBernardo used the 1.440 nm pulsed laser to treat cellulite in 10 patients. The elasticity and skin surface were assessed using specific equipment at baseline and after one, three, six, and 12 months. The results were positive, with an improvement in the skin's irregularity and elasticity; the effects lasted for one year after the treatment.³⁹

This article describes the authors' treatment of cellulite (Curri grade III) in the gluteal region using a 924/975 nm diode laser, with a good clinical response (Figure 6).

EFFECTIVENESS

The efficacy of laser lipolysis is comparable to that of tumescent liposuction, with the additional benefit of promoting skin retraction in the treated area.^{12,15,25,26,36,40,41} Table 3 shows the most relevant clinical studies on laser lipolysis, indicating the treatment area, the type of laser used, and the main results.

The best results are obtained in small and compact areas. Good results were also obtained in the correction of irregulari-

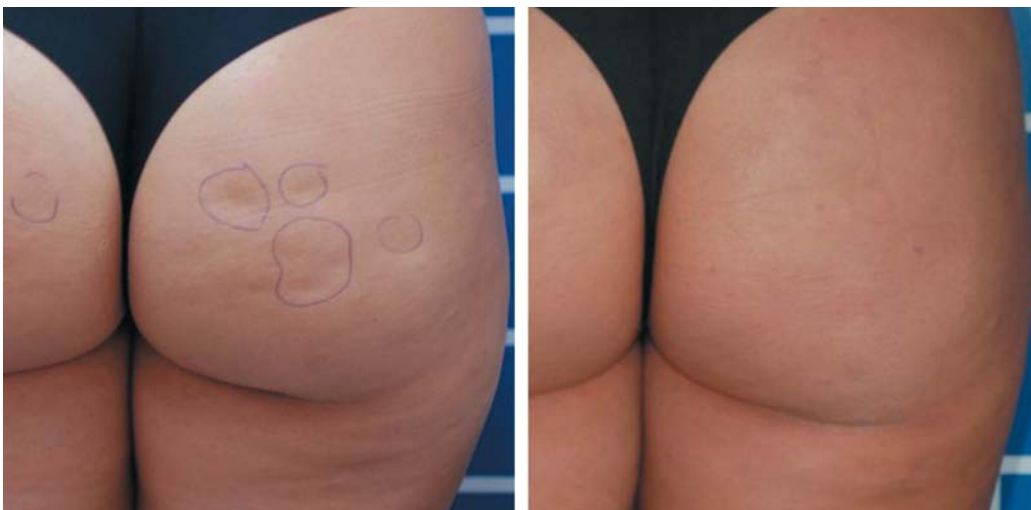

Figure 6: Before and three months after laser lipolysis for the treatment of cellulite

ties from previous liposuctions.⁴

The skin-tightening effect promoted by laser lipolysis is the primary benefit that distinguishes this approach from tumescent liposuction. Although some authors are skeptical about the benefits of laser lipolysis over liposuction, 8 recent comparative studies demonstrated statistically significant results in the retraction effect compared to techniques that do not employ lasers.

In 2010, DiBernardo published a randomized study on the effects of 1.064/1.320 nm laser-based laser lipolysis versus tumescent liposuction in the abdomen of 10 patients. Each patient received one treatment on each side of the abdomen; a blinded evaluator compared the skin contraction in the treated areas. Three months after treatment, the cutaneous retraction in the side that received the laser application was statistically significantly higher (54%).⁴¹

In 2001, Goldman and colleagues compared the skin-tightening effect of 1.064 nm laser-based laser lipolysis versus tumescent liposuction in the arms of 28 patients. Half of the patients were treated with laser lipolysis followed by aspiration, while the other 14 patients received tumescent liposuction only. Independent observers found an average skin retraction of 11.4%, which was statistically greater with the use of laser.²⁵

The rate of patient satisfaction is high in all published clinical studies. Almost all patients reported that they would undergo the procedure again.^{10,23,42-44} Unsatisfactory clinical results were generally associated with low levels of accumulated energy, patients' high expectations, and improper indications of the technique. In 2008, Katz and others described a re-treatment rate of 3.5% – an index lower than that of conventional liposuction, in which 12–13% of cases require new procedures.⁴⁵

SAFETY AND LIMITATIONS

The safety of laser lipolysis is well documented. The technique is safer than liposuction under general anesthesia, and there is evidence of fewer adverse effects than tumescent liposuction.^{3,12}

The more restricted trauma caused by laser lipolysis and the coagulation of small vessels achieved with the technique seem to be responsible for the lower rates of intra-operative bleeding, discomfort, pain, ecchymosis, and swelling in the post-operative period. The liquefaction of fat after administering the laser and the use of cannulas with smaller diameters allow a more effective aspiration with less effort required of the surgeon and less aggression to the tissues.⁴⁶

The studies of Goldman and colleagues³ and Mordon and others⁴⁷ found no association between adipose tissue liquefaction after the use of the laser and increased serum levels of cholesterol and triglycerides. A possible explanation would be the local occlusion of blood and lymph vessels, which hampers the absorption of free fatty acid.

In 2008, Katz and colleagues presented the results of 537 laser lipolysis procedures, which demonstrated no adverse systemic effects. They reported four cases of superficial burns and one case of local infection, corresponding to a rate of 0.93% of adverse effects.⁴⁵

In 2009, Yu and colleagues reported a case of bilateral palpebral burn after laser lipolysis with diode laser for blepharoplasty.⁴⁸

In 2009, Reynaud and others retrospectively evaluated 534 cases and did not observe any cases of burns, infections, hypopigmentation, persistent hematomas, or edemas. Patients resumed their routine activities one and a half days after the procedure. A week later, 83% of patients did not report pain or discomfort.²⁶

In 2012, Kim and others reported three cases of burns after axillary laser lipolysis in the treatment of 29 patients with osmidrosis.³⁵ One hypothesis for the high incidence of adverse effects in this study was the high level of accumulated energy used by the authors (up to 500 J/2 cm²).

The narrow range of treatment comprised between 38°C and 42°C – the range in which laser lipolysis is active – is a subject that deserves attention. An excess of energy in a single area can cause burns to the skin, especially in areas where the dermis is thinner, such as the armpits, face, and neck.⁵

As is the case with any technology that relies on human experience, there is a learning curve in laser lipolysis. Unsatisfactory outcomes result primarily from an excessively low level of applied energy or insufficient accumulated energy in the treated area.

Large areas of the body should not be treated in a single procedure. Best results are obtained when treating small and compact areas.⁴

The treatment duration compared to that of tumescent liposuction is longer, 8 although according to several studies, the technique requires less mechanical effort from the surgeon. Finally, the high cost of the equipment can be a drawback to its use.

PERSPECTIVES

Advances and refinements in the laser lipolysis technique point to the new lasers with wavelengths that can optimize the lipolysis and stimulate neocollagenesis, with a lower risk of adverse effects.⁸

The most recently approved lasers have added measures that increase their safety, featuring internal temperature gauges and motion sensors that prevent the use of excessive energy in a given area, thus reducing the risk of burns and ecchymosis.⁴

Furthermore, smart systems will correlate the total energy applied with the reduction in the volume of fat and the dermal denaturation, determining the optimum fluence to use with minimal epidermal destruction.⁴

Anderson and colleagues observed that there is greater selectivity for fat in the 1,210 nm wavelength.⁴⁹ Therefore, new lasers can be designed to ensure greater specificity for different chromophores.

CONCLUSIONS

Laser lipolysis is an effective and safe therapeutic option in the treatment of localized fat and sagging skin. The use of the technique is increasing, nonetheless it is not expected to replace traditional liposuction.

Laser lipolysis relies on the laser's thermal properties as its

Table 3: Key clinical studies in laser lipolysis

Author	Treated area	Laser	Patients	Main results
Goldman 2002	Multiple areas	1,064 nm Nd:YAG	1734	Safe, effective, and more frequently recommended than liposuction in fibrous areas
Badin 2002	Multiple areas	1,064 nm Nd:YAG	245	Histology corroborates clinical findings
Prado 2006	Multiple areas	1,064 nm Nd:YAG	25	Benefits equivalent to those of traditional liposuction
Kin 2006	Multiple areas	1,064 nm Nd:YAG	30	Results are promising and replicable
Goldman 2006	Submentonian	1,064 nm Nd:YAG	82	Histology shows effectiveness in adipocytolysis and in collagen denaturation
Ichikawa 2006	Axillary osmidrosis	1,064 nm Nd:YAG	17	Total or partial improvement in all patients
Goldman 2008	Cellulite	1,064 nm Nd:YAG	52	84.6% good and excellent results
Goldman 2008	Axillary hyperhidrosis	1,064 nm Nd:YAG	17	83.0% good results; glandular collapse in the histology
Katz 2008	Multiple areas	1,064 nm Nd:YAG	537	No systemic complications; 4 burns and 1 local infection
Woodhall 2009	Arms	1,064 nm Nd:YAG	8	Benefits equivalent to those of traditional liposuction
Rho 2009	Gynecomastia	1,064 nm Nd:YAG	5	CT and US demonstrated decrease
Dudelzak 2009	Arms	1,064 nm Nd:YAG	20	Benefits equivalent to those of traditional liposuction
Sun 2009	Multiple areas	1,064 nm Nd:YAG	35	More fibrous tissues need more accumulated energy
Reynaud 2009	Multiple areas	980 nm diode	334	Very high patient satisfaction; fast post-operative recovery
Weiss 2009	Multiple areas	924/975 nm diode	19	Excellent fat reduction in 73.0%; excellent retraction in 64%
Salzman 2009	Multiple areas	1,064/1,319 nm Nd:YAG	36	Increase in external temperature did not help to determine internal temperature
Goldman 2009	Lipoma	1,064 nm Nd:YAG	20	Effective and minimally invasive option
Woodhall 2009	Multiple areas	1,064 nm Nd:YAG vs. 1,320 nm Nd:YAG	10	30% more skin retraction with 1,320 nm according to patients' evaluation
Woodhall 2009	Multiple areas	1,064/1,320 nm Nd:YAG	20	75% improvement in skin retraction
DiBernardo 2009	Abdomen	1,064/1,320 nm Nd:YAG	5	17% experienced skin retraction after 3 months
McBean 2009	Multiple areas	1,064/1,320 nm Nd:YAG	20	18 had skin retraction; neocollagenesis in the histology
Sasaki 2009	Multiple areas	1,064/1,320 nm Nd:YAG	75	80% clinical improvement after 3 months
Sasaki 2010	Abdomen	1,064/1,320 nm Nd:YAG	3	Collagen denaturation depends on external temperature (38-40°C)
Sadick 2010	Flanks	1,064 nm Nd:YAG	10	Histology with remodeling of the collagen after 6 months; 100% would recommend the procedure
DiBernardo 2010	Abdomen	1,064/1,320 nm Nd:YAG	10	Significantly greater skin tightening with laser lipolysis compared to isolated liposuction
Goldman 2011	Skin tightening	1,064 nm Nd:YAG	28	Greater skin tightening than traditional liposuction
DiBernardo 2011	Cellulite	1,440 nm Nd:YAG	10	Effective and long-lasting results
Stebbins 2011	Lipoma	980 nm diode	1	Effective and minimally invasive technique
Wolferson 2011	Multiple areas	924/975 nm diode	41	Accumulated energy of 5,000 J/10 cm ² was safe and effective; significant and progressive skin tightening
Kotlus 2011	Axillary hyperhidrosis	1,320 nm Nd:YAG	1	Satisfactory results in cases that are resistant to other treatments
Collawn 2011	Multiple areas	1,064/1,320 nm Nd:YAG	72	Effective in the mandibular contour definition; long-lasting results
Holcomb 2011	Face	1,044 nm Nd:YAG	478	Retrospective study of the facial contour treatment; promising therapy
Tagliotatto 2011	Multiple areas	924/975 nm diode	120	High satisfaction rate (90%)
Leclère 2012	Multiple areas	980 nm diode	359	674 procedures; all patients would undergo the procedure again if necessary
Moreno-Moraga 2012	Knees	924/975 nm diode	30	Return to daily activities in 0.92 day
Trelles 2012	Gynecomastia	980 nm diode	28	85.7% of results good and very good
McMenamim 2012	Face	1,064/1,319 nm Nd:YAG and 1,064/1,320 nm Nd:YAG	40	Effective, less invasive, and cost effective compared to surgical face lift
Kim 2012	Axillary osmidrosis	1,064 nm Nd:YAG	29	Total or partial improvement in mild to moderate cases only (n = 19); 3 burns

Kim et al 2006⁵⁰; Goldman 2006⁵¹; Wolferson et al 2011⁵²; Collawn 2011⁵³; Moreno-Moraga et al 2012⁵⁴.

mechanism of action. The thermal energy that is released in the application of the laser directly into the subcutaneous layer leads not only to adipocytolysis and the coagulation of vessels, but also to the stimulation and remodeling of the collagen and elastin, with the resulting skin-tightening effect.

The studies published thus far consistently point out the benefits of less intra-operative bleeding, less discomfort, pain, and ecchymosis in the post-operative period, as well as a faster

recovery time, less mechanical effort for the surgeon, lower complication rates, and the unique benefit of promoting cutaneous retraction.

Although it is well established as an effective and safe alternative to conventional liposuction, laser lipolysis is still a developing technique. Further studies should be carried out in order to optimize the efficacy and safety of the treatment. ●

REFERENCES

1. Resko AE, Magro CM, Diktaban T, Sadick NS. Histological comparison of 1064 nm Nd:YAG and 1320 nm Nd:YAG laser lipolysis using an ex vivo model. *J Drugs Dermatol*. 2009;8(4):377-82.
2. Ahmad J, Eaves FF, Rohrich RJ, Kenkel JM. The American Society for Aesthetic Plastic Surgery (ASAPS) survey: current trends in liposuction. *Aesthet Surg J*. 2011;31(2):214-24.
3. Goldman A, Schavelzon DE, Blugerman GS. Laserlipólise: Lipoaspiração com Nd:YAG Laser. *Rev Soc Bras Cir Plást*. 2002;17(1):17-26.
4. Mordon SR, Plot E. Laser lipolysis versus traditional liposuction for fat removal. *Exp Rev Med Devices*. 2009;6(6):677-88.
5. McBean JC, Katz BE. Laser Lipolysis: Un Update. *J Clin Aesthet Dermatol*. 2011;4(7):25-34.
6. Goldman A, Gotkin RH, Sarnoff DS, Prati C, Rossato F. Cellulite: A New Treatment Approach Combining Subdermal Nd:YAG Laser Lipolysis and Autologous Fat Transplantation. *Aesthetic Surg J*. 2008;28(6):656-62.
7. Klein JA. Tumescent technique for regional anesthesia permits lidocaine doses of 35 mg/kg for liposuction. *J Dermatol Surg Oncol*. 1990;16(3):248-63.
8. Fakhouri TM, Tal AK, Abrou AE, Mehregan DA, Barone F. Laser-Assisted Lipolysis: A Review. *Dermatol Surg*. 2012;38(2):155-169.
9. Tierney EP, Kouba DJ, Hanke CW. Safety of tumescent and laser-assisted liposuction: review of the literature. *J Drugs Dermatol*. 2011;10(12):1363-9.
10. Sadick NS, Diktaban T, Smoller BR. New clinical outcomes utilizing a 1064-nm Nd:YAG laser for lipolysis of the torso oblique region. *J Cosmet Laser Ther*. 2010;12(4):170-5.
11. Apfelberg DB. Results of multicenter study of laser-assisted liposuction. *Clin Plast Surg*. 1996;23(4):713-9.
12. Badin AZD, Moraes LM, Gondek L, Chiaratti MG, Canta L. Laser Lipolysis: Flaccidity Under Control. *Aesth Plast Surg*. 2002;26(5):335-9.
13. Sasaki GH, Tevez A. Laser-assisted liposuction for facial and body contouring and tissue tightening: a 2-year experience with 75 consecutive patients. *Semin Cutan Med Surg*. 2009;28(4):226-35.
14. Wassmer B, Zemmouri J, Rochon P, Mordon S. Comparative study of wavelengths for laser lipolysis. *Photomed Laser Surg*. 2010;28(2):185-8.
15. McBean JC, Katz BE. A pilot study of the efficacy of a 1064 and 1320 nm sequentially firing Nd:YAG laser device for lipolysis and skin tightening. *Lasers Surg Med*. 2009;41(10):779-84.
16. DiBernardo BE, Reyes J, Chen B. Evaluation of tissue thermal effects from 1064/1320-nm laser-assisted lipolysis and its clinical implications. *J Cosmet Laser Ther*. 2009;11(2):62-9.
17. Sasaki GH. Quantification of human abdominal tissue tightening and contraction after component treatments with 1064-nm/1320-nm laser-assisted lipolysis: clinical implications. *Aesthet Surg J*. 2010;30(2):239-45.
18. Mordon SR, Wassmer B, Reynaud JP, Zemmouri J. Mathematical modeling of laser lipolysis. *Biomed Eng Online*. 2008;7:10.
19. Dudelzak J, Hussain M, Goldberg DJ. Laser lipolysis of the arm, with and without suction aspiration: clinical and histologic changes. *J Cosmet Laser Ther*. 2009;11(2):70-3.
20. Mordon S, Eymard-Maurin AF, Wassmer B, Ringot J. Histologic evaluation of laser lipolysis: pulsed 1064-nm Nd:YAG laser versus cw 980-nm diode laser. *Aesthet Surg J*. 2007;27(3):263-8.
21. Seckel BR, Doherty ST, Childs JJ, Smirnov MZ, Cohen RH, Altshuler GB. The role of laser tunnels in laser-assisted lipolysis. *Lasers Surg Med*. 2009;41(10):728-37.

22. Tark KC, Jung JE, Song SY. Superior lipolytic effect of the 1444 nm Nd:YAG laser: comparison with the 1064 nm Nd:YAG laser. *Lasers Surg Med.* 2009;41(10):721-7.
23. Weiss RA, Beasley K. Laser-assisted liposuction using a novel blend of lipid- and water-selective wavelengths. *Lasers Surg Med.* 2009;41(10):760-6.
24. Woodhall KE, Saluja R, Khoury J, Goldman MP. A comparison of three separate clinical studies evaluating the safety and efficacy of laser-assisted lipolysis using 1,064, 1,320 nm, and a combined 1,064/1,320 nm multiplex device. *Lasers Surg Med.* 2009;41(10):774-8.
25. Goldman A, Wollina U, Mundstock EC. Evaluation of tissue tightening by the subdermal Nd:YAG laser-assisted liposuction versus liposuction alone. *J Cutan Aesthet Surg.* 2011;4(2):122-8.
26. Reynaud JP, Skibinski M, Wassmer B, Rochon P, Mordon S. Lipolysis using a 980-nm diode laser: a retrospective analysis of 534 procedures. *Aesthetic Plast Surg.* 2009;33(1):28-36.
27. Rho YK, Kim BJ, Kim MN, Kang KS, Han HJ. Laser lipolysis with pulsed 1064 nm Nd:YAG laser for the treatment of gynecomastia. *Int J Dermatol.* 2009;48(10):1353-9.
28. Trelles MA, Mordon SR, Bonanad E, Moreno-Moraga J, Heckmann A, Unglaub F, et al. Laser-assisted lipolysis in the treatment of gynecomastia: a prospective study in 28 patients. *Lasers Med Sci.* 2012 [Epub ahead of print].
29. Goldman A, Wollina U. Lipoma treatment with a subdermal Nd:YAG laser technique. *Int J Dermatol.* 2009;48(11):1228-32.
30. Saluja R. Dual-wavelength laser lipolysis treatment of lipomas: a case report. *J Drugs Dermatol.* 2010;9(4):387-8.
31. Stebbins WG, Hanke CW, Petersen J. Novel method of minimally invasive removal of large lipoma after laser lipolysis with 980 nm diode laser. *Dermatol Ther.* 2011;24(1):125-30.
32. Ichikawa K, Miyasaka M, Aikawa Y. Subcutaneous Laser Treatment of Axillary Osmidrosis: A New Technique. *Plast Reconstr Surg.* 2006;118(1):170-4.
33. Goldman A, Wollina U. Subdermal Nd-YAG Laser for Axillary Hyperhidrosis. *Dermatol Surg.* 2008;34(6):756-62.
34. Kotlus BS. Treatment of refractory axillary hyperhidrosis with a 1320-nm Nd:YAG laser. *J Cosmet Laser Ther.* 2011;13(4):193-5.
35. Kim D, Kim J, Yeo H, Kwon H, Son D, Han K. Treatment of Axillary Osmidrosis Using a Subcutaneous Pulsed Nd-YAG. *Laser Arch Plast Surg.* 2012;39(2):143-9.
36. Sun Y, Wu S, Yan S, Shi H, Chen D, Chen Y. Laser Lipolysis Used to Treat Localized Adiposis: A Preliminary Report on Experience with Asian Patients. *Aesth Plast Surg.* 2009;33(5):701-5.
37. Holcomb JD, Turk J, Baek SJ, Rousso DE. Laser-assisted facial contouring using a thermally confined 1444 nm Nd:YAG laser: a new paradigm for facial sculpting and rejuvenation. *Facial Plast Surg.* 2011;27(4):315-30.
38. McMenamin P. Laser Face-Lifts: A New Paradigm in Face-Lift Surgery. *Facial Plast Surg.* 2011;27(4):299-307.
39. DiBernardo BE. Treatment of cellulite using a 1440-nm pulsed laser with one-year follow-up. *Aesthet Surg J.* 2011;31(3):328-41.
40. Prado A, Andrade P, Danilla S, Leniz P, Castillo P, Gaete F. A prospective, randomized, double-blind, controlled clinical trial comparing laser-assisted lipoplasty with suction-assisted lipoplasty. *Plast Reconstr Surg.* 2006;118(4):1032-45.
41. DiBernardo BE. Randomized, blinded split abdomen study evaluating skin shrinkage and skin tightening in laser-assisted liposuction versus liposuction control. *Aesthet Surg J.* 2010;30(4):593-602.
42. Wong L, Vasconez HC. Patient satisfaction after Nd:YAG laser-assisted lipolysis. *Ann Plast Surg.* 2011;66(5):561-3.
43. Tagliototto S, Medeiros VB, Teresani PCS, Leite OG, Filipe JV, Mazzaro CB, et al. Experiência em laserlipólise: casuística de 120 casos no período de 2004 a 2010. *Surg Cosmet Dermatol.* 2011;3(4):282-7.
44. Leclère FM, Trelles M, Moreno-Moraga J, Servell P, Mordon SR. 980 nm Laser Lipolysis (LAL): About 674 Procedures in 359 patients. *J Cosmet Laser Ther.* 2012 [Epub ahead of print].
45. Katz B, McBean J. Laser-assisted lipolysis: a report on complications. *J Cosmet Laser Ther.* 2008;10(4):231-33.
46. Ichikawa K, Tanino R, Wakaki M. Histologic and photonic evaluation of a pulsed Nd:YAG laser for ablation of subcutaneous adipose tissue. *Tokai J Exp Clin Med.* 2006;31(4):136-40.
47. Mordon S, Wassmer B, Rochon P, Desmyttere J, Grard C, Stalnikiewicz G, et al. Serum lipid changes following laser lipolysis. *J Cosmet Laser Ther.* 2009;11(2):74-7.
48. Yu D, Biesman B, Khan JA. Bilateral dermal burn from subcutaneous diode laser lipolysis blepharoplasty. *Lasers Surg Med.* 2009;41(9):609-11.
49. Anderson R et al. Selective Photothermolysis of Lipid-Rich Tissues: A Free Electron Laser Study. *Lasers Surg Med.* 2006;38:913-9.
50. Kim KH, Geronemus RG. Laser lipolysis using a novel 1064 nm Nd:YAG laser. *Dermatol Surg.* 2006;32(2):241-8.
51. Goldman A. Submental Nd:YAG laser-assisted liposuction. *Lasers Surg Med.* 2006;38(2):181-84.
52. Wolfenson M, Roncatti C, Alencar AH, Barros T, Silva Neto JF, Santos Filho FCN. Laserlipólise: redução da pele e prevenção de umbigo flácido nas lipoplastias seguindo parâmetros de segurança no uso do laser de diodo - com duplo comprimento de onda 924 e 975 nm. *Rev Bras Cir Plást.* 2011;26(2):259-65.
53. Collawn SS. Smartilipo MPX sculpting of the body and face. *J Cosmet Laser Ther.* 2011;13(4):172-5.
54. Moreno-Moraga J, Trelles MA, Mordon S, Unglaub F, Bravo E, de la Torre JR, et al. Laser-Assisted lipolysis for Knee Remodeling: A Prospective Study in 30 Patients. *J Cosmet Laser Ther.* 2012 [Epub ahead of print].