

Safety and efficacy evaluation of a new hyaluronic acid based filler in the treatment of nasolabial folds and lips outline

Avaliação da segurança e eficácia de novo preenchedor à base de ácido hialurônico no tratamento dos sulcos nasolabiais e contorno dos lábios

ABSTRACT

Introduction: The use of dermal filling techniques for soft tissue augmentation has greatly increased in recent years. Hyaluronic acid is one of the most used temporary dermal fillers in the treatment of facial wrinkles, furrows, and folds due to its effectiveness and safety.

Objective: To evaluate the efficacy and safety of Perfectha®, a new hyaluronic acid filler, for nasolabial folds and lip correction.

Methods: Open, multicenter study comprising 87 women. Efficacy was evaluated by the Global Aesthetic Improvement Scale and the Wrinkle Severity Rating Scale. Safety was evaluated through observation and the reporting of side effects.

Results: One week after the injection of the filler, improvement in nasolabial folds and lips was observed in 86% and 89% of the women, respectively. Mild or moderate transient inflammatory reaction and ecchymoses occurred in 15% and 9% of patients, respectively, mainly in nasolabial folds. Two patients presented labial herpes simplex after treatment of the lips. The good results were maintained in 76% and 57% of women for nasolabial folds and in 72% and 45% of women for lips after 3 and 6 months, respectively.

Conclusion: Perfectha® was effective and safe for these indications.

Keywords: hyaluronic acid; skin; inflammation.

RESUMO

Introdução: o uso da técnica de preenchimento cutâneo vem crescendo nos últimos anos. O ácido hialurônico é um dos preenchedores dérmicos temporários mais usados na correção de rugas, linhas e sulcos faciais por ser seguro e eficaz.

Objetivo: avaliar a eficácia e segurança do produto Perfectha®, novo preenchedor à base de ácido hialurônico, para a correção dos sulcos nasolabiais e contorno dos lábios.

Métodos: estudo aberto, multicêntrico, não randomizado, não controlado, incluindo 87 mulheres saudáveis. A avaliação da eficácia foi realizada através das escalas de melhora estética global (Global Aesthetic Improvement Scale - GAIS) e da classificação de gravidade das rugas (Wrinkle Severity Rating Scale - WSRS). A segurança foi avaliada por observação e relato de eventos adversos.

Resultados: uma semana após a aplicação do preenchedor, foi observada melhora nos sulcos nasolabiais de 86% das mulheres e nos lábios de 89% delas. Reação inflamatória, transitória, leve ou moderada e equimoses ocorreram em 15% e 9% das pacientes, respectivamente, sobretudo nos sulcos nasolabiais. Duas pacientes apresentaram herpes simples labial após o tratamento dos lábios. Os bons resultados se mantiveram em 76% e 57% das mulheres, nos sulcos nasolabiais e em 72% e 45% delas nos lábios, após três e seis meses, respectivamente.

Conclusão: o preenchedor Perfectha® mostrou-se eficaz e seguro para essas indicações.

Palavras-chave: ácido hialurônico; pele; inflamação.

Original article

Authors:

Sergio Talarico¹
 Karime Marques Hassun²
 Érica de Oliveira Monteiro³
 Meire Odete Brasil Parada⁴
 Laura Bariquelo Buratini⁵
 Lúcia Arruda²
 Ediléia Bagatin⁷

¹ Associate Professor at the Department of Dermatology, São Paulo State Federal University (Unifesp) – São Paulo (SP), Brazil

² Physician, São Paulo State Federal University (Unifesp) – São Paulo (SP), Brazil

³ Collaborating Physician, São Paulo State Federal University (Unifesp) – São Paulo (SP), Brazil

⁴ Collaborating Physician, Discipline of Dermatology, São Paulo State Federal University (Unifesp) – Botucatu (SP), Brazil

⁵ Head of the Dermatology Service, Pontifical Catholic University of Campinas (Puccamp) – Campinas (SP), Brazil

Correspondence:

Sergio Talarico
 Rua Estado de Israel, 192 - Vila Clementino
 04022 000 - São Paulo - SP, Brazil
 Tel.: +55 11 5549 7888
 Email: talarico@talaricodermatologia.com.br

Received on: 12/03/2010
 Approved on: 15/04/2010

This study was conducted at the Federal University of São Paulo (Unifesp) – São Paulo (SP), Brazil.

Conflicts of interest: none
 Financial support: none

INTRODUCTION

The search for non-invasive methods, as well as for new technologies, drugs and other products for correcting cutaneous alterations linked to the aging process is an increasingly significant trend. The technique of dermal filling is among the most used non-surgical procedures and when implemented with hyaluronic acid (HA) ranks second among the five more frequently performed in the United States.¹ Dermal fillers containing HA are the filler of choice for correcting wrinkles, folds, depressions, acne scars, improving the outline and volume of the lips, and replacing facial volume. Multiple products, with varying physical and chemical features – and resulting effects – are available.² Several products are registered and approved for usage in Brazil, raising the importance of verifying the availability of clinical studies and following up the information released by pharmacovigilance in order to assure their efficacy and, more importantly, their safety. The efficacy of HA has been already demonstrated in several studies.^{3,4} The adverse effects are classified in immediate and delayed, and can vary from ecchymose, light oedema and erythema, and even necrosis. The immediate reaction to the application of HA usually consists of foreseeable light inflammation that can vary in intensity and duration, depending on the product, application technique, asepsis care and individual immunological response.⁵⁻⁸

OBJECTIVE

To evaluate the efficacy and safety of the HA based filler Perfectha®, following the application in the nasolabial folds and labial outline.

METHODS

This was an open, multicenter study of a therapeutic intervention, conducted at the Federal University of São Paulo – Unifesp, the University of the State of São Paulo/Botucatu Campus – Unesp, and Pontifical Catholic University of Campinas – Puccamp. Following approval by the Committee of Ethics in Research of Unifesp/HSP, women who met the inclusion and exclusion criteria and signed the term of free and informed consent were included. The inclusion criteria were: healthy women, between 20 and 50 years old, with an indication for filling the nasolabial folds and lips. The exclusion criteria were: the use of medication that could interfere with coagulation (acetylsalicylic acid, anticoagulant, ginkgo biloba, and vitamin E), a history of hypersensitivity or allergy to any component of the product, lesion in the place of application, presence of autoimmune illnesses, pregnancy or breastfeeding and a history of implants in the area.

The product applied was Perfectha® (ObvieLine 8, Chemin du Jubin – 69570 Dardilly, France), which contains HA of non-animal source, with low concentration of protein residues (< 0.25% $\mu\text{g/g/ml}$). The product was approved for commercialization in Brazil by the Brazilian National Agency of Sanitary Surveillance – Anvisa in

2005. The product is stabilized with cross-links made

with the 1,4-butanediol diglycidyl ether. Perfectha Derm® in its 24mg/g concentration was used.

Patients received, in a single visit, injections of 1 ml on each side of the nasolabial folds, and 1 ml in the superior and inferior labial outline, with a 27G needle. Retrograde linear injections were administered in the medium dermis after the application of topical anesthesia with a eutectic blend of lidocaine and prilocaine in equal parts. The patients were instructed not to manipulate the area, not to use makeup during the first 24 hours, not to expose to the sun or excessive heat, to use SPF 30 sunscreen daily, and not to carry out sport activities during the week of the application. No other treatment was performed during the study.

The clinical efficacy evaluation – i.e., assessing the correction of the nasolabial folds and the improvement of the outline of the lips – was conducted using the patients' and investigators' opinions and pictures obtained on the day of the injection, one hour after and, seven, 30, 60, 90 and 180 days after. The pictures were analyzed by two independent dermatologists using the Global Aesthetic Improvement Scale (GAIS)⁴ and the Wrinkle Severity Rating Scale (WSRS)⁹, described below. Safety was evaluated by the observation and report of immediate and/or delayed, light, moderate or serious adverse events such as erythema, edema, ecchymose, visible nodules and/or palpable and other unexpected symptoms.

RESULTS

Women between the ages of 39 and 49 (n=87) were treated. Of these, 58 and 29 received filler in the nasolabial folds and lips, respectively. One week after treatment, “much improved” and “very much improved” appearances were observed in 86% of patients. The adverse events occurred as follows: inflammatory reaction characterized by light or moderate and transient erythema and edema in 25% of patients, mainly in the nasolabial folds; ecchymoses in 9% of patients; and herpes simplex in two patients following the

Global Aesthetic Improvement Scale (GAIS)

3. Very much improved: Highly satisfactory cosmetic result after injection.
2. Much improved: Accentuated improvement in the appearance as compared to the initial condition, but not completely satisfactory for the patient. A complementary application would improve the result slightly.
1. Improved: Obvious improvement in the appearance as compared to the initial condition. A complementary implant or retreatment would be suitable.
0. No change: The appearance essentially resembles the original condition.
- 1. Worse: The appearance is worse than that of the original condition.

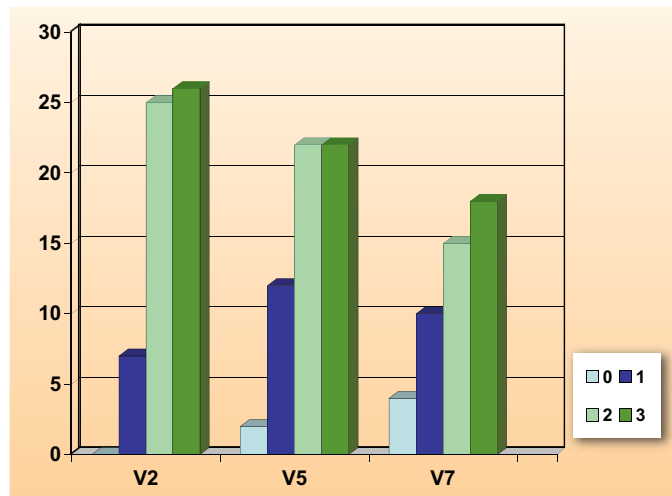
Wrinkle Severity Rating Scale (WSRS) ⁹

Grade	Description
5. Very serious	Extreme. Long and extremely deep folds to the detriment of the facial appearance. On stretching out the skin it is possible to observe V-shaped variable folds of 2 to 4 mm.
4. Serious	Deep and long folds, prominent facial appearance, bends with less than 2 mm when the skin is stretched out.
3. Moderate	Folds moderately deep; although the facial appearance is normal, the difference becomes visible when the skin is stretched out.
2. Superficial	Superficial, but discreet indenting can be observed in the fold; discreet influence on the facial appearance.
1. Absent	Fold not visible. Continuous cutaneous line.

filling of the lips. The highly satisfactory and excellent results in the nasolabial folds remained in 76% and 57%, and in the lips in 72% and 45% of the women, after three and six months, respectively (Tables 1 and 2; Figures 1 and 2).

DISCUSSION

This study showed that the filler Perfectha Derm® was effective and safe for nasolabial fold corrections and application in the lips; it improved the outline and increased the volume. The duration of the effect was comparable with that of other temporary fillers.¹⁰ The possibility of lengthening the effect, even if only partially has been discussed: this would be caused by stimulating the fibroblasts by the mechanical action of the filler and not by cellular interactions and the production of new



Graph 1: Efficacy of filling with Perfectha Derm® in the nasolabial folds, 7 (visit 2 or V2), 90 (visit 5 or V5) and 180 (visit 7 or V7) days after application, according to the Global Aesthetic Improvement Scale

Table 1 - Efficacy of filling with Perfectha Derm® in nasolabial folds, according to the Global Aesthetic Improvement Scale

Day	7	90	180
0 = no change	0	2	4
1 = improved	7	12	10
2 = much improved	25	22	15
3 = very much improved	26	22	18

(11 losses)

Tabela 2 - Efficacy of filling with Perfectha Derm® in the lips, according to the Global Aesthetic Improvement Scale

Day	7	90	180
0 = no change	0	2	5
1 = improved	3	6	6
2 = much improved	1	9	4
3 = very much improved	25	12	9

(5 losses)

collagen tissue.¹¹ The intensity of the inflammatory reaction varied from light to moderate, beginning soon after application and ending spontaneously up to seven days later. These reactions are comparable to similar studies in the literature, which report inflammation ranging from one to two days¹² up to eight days.¹³ Serious adverse events are more frequently described in association with the use of permanent fillers.⁸ Notwithstanding, some studies report delayed and serious undesirable reactions related to HA.¹⁴ Many variables can influence the occurrence and permanence of the inflammatory process, including differences in the properties of the several HA-based fillers, application technique, depth of the injection, individual sensibility and differences in the studied populations. It has been suggested that the protein residues that cannot be totally eliminated during the manufacturing process may be the cause of the inflammatory process, the formation of granulomas, the production of antibodies and the hypersensitivity reactions.¹⁵ In

Table 3 -Distribution of patients according to the treated area and the immediate reaction to the treatment

Immediate reaction	LO	NLF
	(n=29)	(n=58)
No	21 (72,5%)	42 (72,5%)
Yes	8 (27,5%)	16 (27,5%)

CL = contorno dos lábios

SNL= sulco nasolabial

this study, no type of delayed reaction was observed.

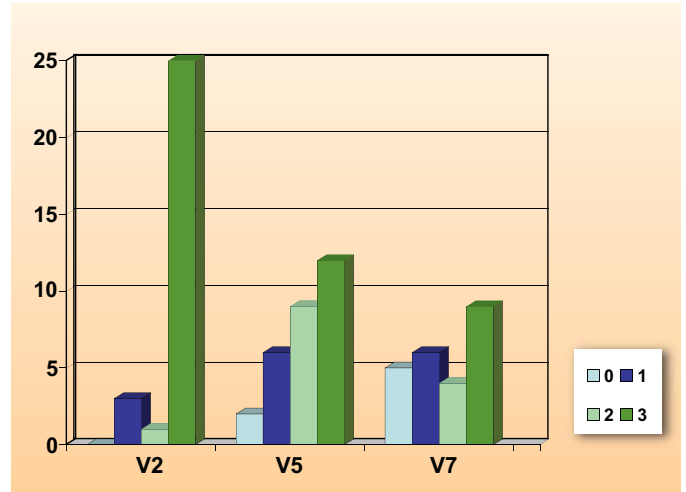
In order to obtain good results without serious complications, it is important that the physician is able to recommend the appropriate procedure, select the patient judiciously, know the chosen product well, and master the application technique. Additionally, the physician must be aware of possible complications and know how to recognize and treat them quickly and effectively.¹⁶

CONCLUSION

The new HA-based product Perfectha Derm[®] was shown to be effective and safe for the correction of nasolabial folds and the improvement of lips outline and volume in adult women. Immediate reactions were foreseeable and mild, and results lasted up to 180 days after application. ●

REFERENCES

- Sagrillo DP. Emerging trends with dermal fillers. *Plast Surg Nurs*. 2008; 28(3):152-3.
- Tezel A, Fredrickson GH. The science of hialuronic acid dermal fillers. *J Cosmet Laser Ther*. 2008; 10(1):35-42.
- DeLorenzi C, Weinberg M, Solish N, Swift A. A multicenter study of the efficacy and safety of subcutaneous nonanimal stabilized hyaluronic acid in aesthetic facial contouring: Interim Report. *Dermatol Surg*. 2006;32(2): 205-11.
- Narins RS, Brandt F, Leyden J, Lorenc ZP, Rubin M, Smith S. A randomized, double blind, multicenter comparison of the efficacy and tolerability of Restylane versus Zyplast for the correction of nasolabial folds. *Dermatol Surg*. 2003; 29(6):588-95.
- Gladstone HB, Cohen JL. Adverse effects when injecting facial fillers. *Semin Cutan Med Surg*. 2007; 26(1):34-9.
- Dadzie OE, Mahalingam M, Parada M, El Helou T, Philips T, Bhawan J. Adverse cutaneous reactions to soft tissue fillers - a review of the histological features. *J Cutan Pathol*. 2008; 35(6):536-48.
- Lowe NJ, Maxwell CA, Lowe P, Duick MG, Shah K. Hyaluronic acid skin fillers: adverse reactions and skin testing. *J Am Acad Dermatol*. 2001; 45(6):930-3.
- Parada MB, Michalany NS, Hassun KM, Bagatin E, Talarico S, A histologic study of adverse effects of different cosmetic skin fillers. *SkinMed*. 2005; 4(6):345-9.
- Day DJ, Littler CM, Swift RW, Gottlieb S. The wrinkle severity rating scale - a validation study. *Am J Clin Dermatol*. 2004; 5(1):49-52.
- Lemperle G, Morhenn V, Charrier U. Human histology and persistence of various injectable filler substances for soft tissue augmentation. *Aesthetic Plast Surg*. 2003; 27(5):354-66.
- Wang F, Garza LA, Kang S, Varani J, Orringer JS, Finger GJ, et al. In vivo stimulation of de novo collagen production caused by cross-linked hyaluronic acid dermal filler injections in photodamaged human skin. *Arch Dermatol*. 2007; 143(2):155-63.
- Duranti F, Salti G, Bovani B, Calandra M, Rosati ML. Injectable hyaluronic acid gel for soft tissue augmentation. A clinical and histological study. *Dermatol Surg*. 1998;24(12): 1317-25.
- Micheels P. Human anti-hyaluronic acid antibodies: is it possible? *Dermatol Surg*. 2002; 28(4):359-60.
- Pinheiro MVB, Bagatin E, Hassun KM, Talarico S. Adverse Effect of Soft Tissue Augmentation with Hyaluronic Acid. *Original Contributions. J Cosmet Dermatol*. 2005; 4(3):184-6.
- Friedman PM, Mafong EA, Kauvar AN, Geronemus RG. Safety data of injectable nonanimal stabilized hyaluronic acid gel for soft tissue augmentation. *Dermatol Surg*. 2002; 28(6):491-4.
- Cohen JL. Understanding, avoiding and managing dermal filler complications. *Dermatol Surg*. 2008; 34(Suppl 1):S92-S99.



Graph 2: Efficacy of filling with Perfectha Derm[®] in the lips, 7 (visit 2 or V2), 90 (visit 5 or V5) and 180 (visit 7 or V7) days after application, according to the Global Aesthetic Improvement Scale