

10% thioglycolic acid gel peels: a safe and efficient option in the treatment of constitutional infraorbital hyperpigmentation

Peeling de gel de ácido tioglicólico 10%: opção segura e eficiente na pigmentação infraorbicular constitucional

ABSTRACT

Introduction: Constitutional infraorbital hyperchromia (commonly called under-eye circles) is a common dermatosis that is difficult to treat.

Objective: To evaluate the clinical improvement of constitutional infraorbital pigmentation resulting from the application of a series of five 10% thioglycolic acid gel peeling sessions.

Methods: Patients were administered five successive 10% thioglycolic acid gel peel sessions, in 15-day intervals. In the first session, the product was left on for two minutes, with three minutes added in each subsequent session, culminating with 15 minutes of contact in the last session. Fifteen days after the last session, a satisfaction scale ranging from 0 (lack of improvement) to 10 (total improvement) was administered to the patients, to the dermatologist investigating the peelings, and to a blind-evaluator medical doctor (a dermatologist that had not had taken part in the treatment sessions).

Results: Study subjects (n=10) were females aged 24–50. The average clinical satisfaction presented by the patients, the investigator, and the blind-evaluator were 7.8, 7.6 and 6.8, respectively, with no statistically significant differences among them ($p=0.065$).

Conclusion: The serial application of 10% thioglycolic acid gel peels is a safe, efficient, and cost-effective treatment for constitutional infraorbital pigmentation.

Keywords: chemexfoliation; eye; hyperpigmentation; eyelid diseases.

RESUMO

Introdução: A hiperchromia infraorbicular constitucional é dermatose comum, de difícil tratamento.

Objetivo: Avaliar a melhoria clínica da pigmentação infraorbicular constitucional com cinco peelings seriados de ácido tioglicólico a 10% em gel.

Métodos: 10 voluntárias do sexo feminino, entre 24 e 50 anos de idade, realizaram cinco sessões quinzenais de peeling de ácido tioglicólico 10% gel. Na primeira sessão, o produto foi deixado por dois minutos, acrescentando-se três minutos a cada uma das sessões subsequentes, tendo na última sido deixado por 15 minutos; 15 dias após a última sessão, foi aplicada escala de satisfação clínica, de 0 (ausência de melhora) a 10 (melhora total), tanto às pacientes quanto ao médico aplicador e a um médico avaliador-cego.

Resultados: A média da satisfação clínica apontada pelas pacientes foi 7,8; a do médico aplicador, 7,6; e a do médico avaliador-cego, 6,8, sem diferenças estatísticas entre eles ($p=0,065$).

Conclusão: Os peelings seriados de ácido tioglicólico 10% em gel são alternativa segura, eficiente e barata para a abordagem da pigmentação infraorbicular constitucional.

Palavras-chaves: abrasão química; olho; hiperpigmentação; doenças palpebrais.

Authors:

Adilson Costa¹
Arthur Volpe D'Angieri Basile²
Vanessa Lucília Silveira Medeiros³
Thaís Abdalla Moisés⁴
Fernanda Sayuri Ota⁵
Jimmy Adans Costa Palandi⁶

¹ Coordinator of Ambulatory of Pregnancy Acne, Cosmiatry and Dermatology at the Dermatologic Clinical Research Nucleus; and of the Programme of Medical Residency in Dermatology – Pontifical Catholic University of Campinas (PUC-Campinas) – Campinas (SP), Brazil; Master in Dermatology from the Federal University of São Paulo (Unifesp/EPM) – São Paulo (SP), Brazil.

² Former dermatology resident at the Dermatologic Service of the Hospital and Maternity Celso Pierro, from the Pontifical Catholic University of Campinas (HMCP/PUC-Campinas) – Campinas (SP), Brazil.

³ Former dermatology resident at the Dermatologic Service of the Hospital and Maternity Celso Pierro, from the Pontifical Catholic University of Campinas (HMCP/PUC-Campinas) – Campinas (SP), Brazil.

⁴ Dermatology resident at the Dermatologic Service of the Hospital and Maternity Celso Pierro, from the Pontifical Catholic University of Campinas (HMCP/PUC-Campinas) – Campinas (SP), Brazil.

⁵ Dermatology resident at the Dermatologic Service of the Hospital and Maternity Celso Pierro, from the Pontifical Catholic University of Campinas (HMCP/PUC-Campinas) – Campinas (SP), Brazil.

⁶ Statistician, owner of Adans Estatística - São Paulo (SP), Brazil.

Correspondence:

Adilson Costa
Rua Original, 219 – Vila Madalena
05435 050 São Paulo SP Brazil
Tel./fax: +55 11 3034 1170, +55 11 3034 1932
E-mail: adilson_costa@hotmail.com

Received on: 10/01/2010

Accepted for publication on: 20/02/2010

This study was performed by the Dermatologic Service of the Hospital and Maternity Celso Pierro, from the Pontifical Catholic University of Campinas (HMCP/PUC-Campinas).

Conflicts of interest: None
Financial support: None

INTRODUCTION

The constitutional periorbicular hyperpigmentation, commonly known as under-eye circles, may have an important impact on patients' quality of life ¹. Its prevalence is similar among genders; however, the greater number of medical complaints from women is notable, particularly from brown-haired people. In spite of the few studies available on the etiology of this disorder, it is known that it has a dominant autosomal characteristic ^{1,2}.

The causes of this condition have not yet been clearly elucidated. Several factors may contribute to its occurrence, such as the increase of melanin in the eyelids' epidermis, the post-inflammatory pigmentation in people with atopic dermatitis, the shading of the skin due to flaccidity and excess, and atrophy of the skin that causes the vascular plexus to become visible. Persistent insomnia and fatigue also contribute to the condition through the stasis of the blood vessels, leading to a change in the color of the area. Occasionally, some drugs such as antipsychotics, chemotherapeutics, and some eye drops may cause a darkening of the skin around the eye (1-5).

Different treatments have been proposed, although few have promoted satisfactory and lasting improvement. Among those options are: cryosurgery; intense pulsed light; CO2 Lasers, Argon, Ruby and Excimer; retinoids; dermabrasion; and chemical peelings. A therapeutic response requires several sessions of any of these procedures, thus demanding that patients be advised of the slow process of improvement and of the importance of maintaining treatment continuity. Photoprotection is indispensable ^{3,4,6}. Among new techniques, chemical peeling is considered a simple, low-cost procedure that does not require complex instruments. Its action consists of the partial or complete destruction of the epidermis (sometimes including the dermis), which promotes the exfoliation and removal of superficial injuries, followed by the regeneration of the epidermis and the dermic tissue ⁶.

The more common side effects of chemical peelings are acneiform eruptions, milia, allergic reactions, change in the texture of the skin, and post-inflammatory hyper or hypopigmentation. The best way to avoid such complications is to identify risk factors and individualize the therapeutics (1-6). In this article, thioglycolic acid is presented as a possible agent in the approach of the constitutional periorbicular hyperpigmentation. Also called mercaptoacetic acid, thioglycolic acid is a compound that includes sulphur, with a molecular weight of 92.12 (between trichloroacetic and glycolic acids, which are 163.4 and 76.05, respectively). It is highly water, alcohol and ether soluble, and easily oxidable ^{7,8}.

In the treatment of hemosiderotic hyperchromias, it is topically used in concentrations from 5% to 12%. Its affinity with iron is similar to that of the apoferritin, entailing the capacity to chelate the iron in the hemosiderin due to the presence of the thiolic group ^{7,8}.

The objective of this study is to evaluate the clinical safety and effectiveness of serial applications of thioglycolic acid in the therapeutic management of the constitutional periorbicular hyperchromia.

METHODS

An open, non-paired, monocentric, not randomized clinical pilot study was conducted in which patients with constitutional infraorbital hyperchromia were administered serial peelings of 10% thioglycolic acid in gel. The study was carried out in accordance with all international standards and the Brazilian Good Clinical Practices of Research in Human Beings. Study subjects received five sessions of peelings with 10% thioglycolic acid, delivered in gel, at 15-day intervals. The duration of the first application of the chemical agent was two minutes; three minutes were added to the duration of each subsequent session, culminating in a 15-minute final application.

Initially, the periorbicular area was degreased with an 50% alcohol solution. Next, 10% thioglycolic acid is applied to the area of the inferior eyelid using a cotton swab, preserving the cosmetic unit.

Once the session duration elapsed, while the patient is still lying down, the product was removed with gauze and the area was washed with water. Within two or three days of application, the skin is expected to become erythematous, sometimes with fine and brownish crusts, with discreet palpebral oedema. The complete process can take up to seven days to complete and it is directly linked to the duration of exposure to the product.

The photographic records (before and after and the degree of satisfaction with the results (on a scale of 0 to 10) were used as evaluation parameters, both for the physician conducting the applications and the patient.

RESULTS

A level of significance of 0.05 (5%) was determined for this study, with confidence intervals of 95% for all analyzed variables. Due to the absence of conditions (suppositions) for the use of parametric techniques, such as the normality (Anderson-Darling Test) and homoscedasticity (homogeneity of the variances; Levene's Test), non-parametric tests were employed in this study.

This study was conducted on patients with constitutional infraorbital hyperchromia (n=10). Study subjects were aged 24 to 50 years (average 35.3 years) and had skin phototypes I to IV. After the application of the protocol, all the volunteers reported almost immediately a bearable sensation of burning that intensified with the permanence of the 10% thioglycolic acid on the skin. It was possible to complete the protocol according to the preset terms in all patients. A few seconds after the application, discreet erythema and oedema were observed, in addition to frosting grade II, which appeared during the sessions. Frosting grade II that lasted an average of five minutes, coinciding with the second application, was verified in all patients. Those developed a discreet edema, restricted to the applied region, and an erythema with an average permanence of five days. The formation of a fine, discreetly brownish crust began on the second day after application and started to peel on the seventh day after the procedure, at most.

After the completion of the five serial peelings on the inferior eyelid, both the physician applying the substance and the patients attributed marks from 0 (absence of improvement) to 10 (total improvement), representing the degree of satisfaction with the clinical response. In addition, a team member (a blind-evaluator dermatologist) who had not participated in the study evaluated the

pictures of the pre and post peeling periods. Without knowing the sequence in which the pictures were taken, the evaluator used the same scale to grade the pictures thought to be taken after the procedure. The results from the grading, as well as the patients' demographic data, are shown in Table 1.

The average clinical marks given by the applicator physician, the patients, and the blind-evaluator dermatologist regarding the clinical results obtained with the treatment were 7.6, 7.8, and 6.8, respectively (Figure 1). There were no statistically significant differences among them ($p=0.065$ for the Friedman's Test, that evaluates paired data).

At the end of the treatment, the blind-evaluator dermatologist succeeded in noticing the clinical improvement in all patients – i.e., she correctly classified the pictures as before and after treatment.

DISCUSSION

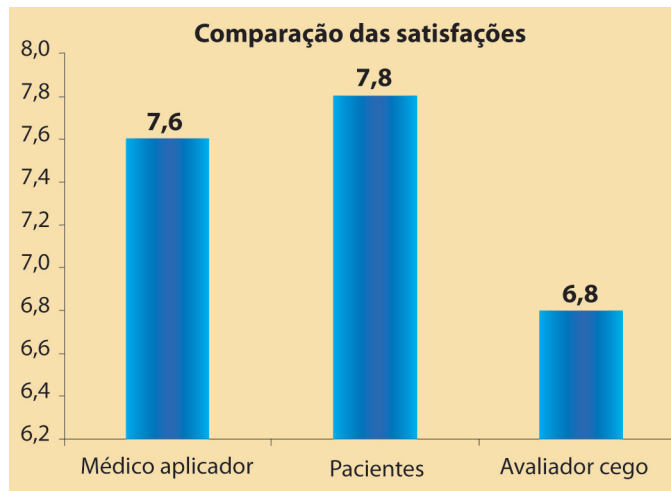
Eye circles represent a common and stigmatizing complaint ¹. Although there are several determinant factors, hyperchromia, due to the deposit of iron, is perhaps the most important one. It is

believed that cutaneous hyperchromia is a consequence of the deposit of hemosiderin, given that it results from the biogenic transformation of the group heme of the hemoglobin, when there is dermic blood extravasation; at that moment, the liberation of that group's iron ions takes place, entailing the formation of free radicals that consequently stimulate the melanocit, generating the associated melanotic pigmentation ⁷. Clearly, insomnia and persistent fatigue contribute to the worsening of that process, causing the stasis of the blood vessels and leading to a change in the color of the area (1-6).

Thioglycolic acid is one of the representatives of the thioglycolates class, whose substances, such as corporal depilatories, hair smoothers and colorants ⁸ have been employed by the cosmetic industry for a long time. The substances of this class may present irritation and cutaneous sensitization capacity ⁷. It has been proven that these substances definitely do not present a mutagenic, carcinogenic, embryogenic, or toxic profile in a dose of up to 100mg/kg/day ⁸ in mice. A maximum concentration of 15.4% thioglycolic acid can be safely used occasionally as a topical cosmetic ⁸.

Thioglycolic acid is an organic substance (8). It is normally found at 10% concentration in gel as a chemical peeling agent to treat constitutional periocular hyperchromia; its has been proven an excellent therapeutic substance to treat that dermatosis. As shown in this article and in line with data from the related literature, its cutaneous application causes a slight discomfort, associated with a discreet erythema, with light or transitory desquamation and, rarely, sensitization. Thioglycolic acid is considered a compound of low ocular toxicity and if by chance the ocular conjunctiva is exposed to it, the latter should be washed vigorously, according to orientation already established for cosmetic products that contain thioglycolic acid ^{7,8}.

In this study, all patients reported some degree of clinical satisfaction with the serial application of 10% thioglycolic acid to treat under-eye circles. The arithmetic mean of the scores for personal satisfaction was of 7.8 (in a scale from 0 to 10), statistically congruent to those attributed by the applicator physician (7.6) and by the blind-evaluator dermatologist (6.8) (Figure 1).



Graph 1: Comparison of clinical satisfaction of the physician, the patients and the blind-evaluator

Table 1 - Summary of patients' demographic data, clinical satisfaction notes of physician and patients, and blind-evaluator dermatologist's clinical evaluation following the treatment of constitutional hyperchromia periorbicular with 10% thioglycolic acid peeling

Patient number	Initials	Age	Phototype	Clinical satisfaction (physician)	Clinical satisfaction (patients)	Clinical satisfaction (blind-evaluator)
1	ESS	32	IV	8	7	8
2	AH	24	II	8	8	8
3	CIDR	47	II	8	9	8
4	VLM	29	II	8	8	6
5	RF	26	I	8	6	5
6	VSA	25	III	7	7	6
7	AC	34	III	7	9	6
8	CP	51	II	7	9	7
9	MGA	50	IV	7	7	7
10	EW	57	IV	8	8	7

Table 2 - Statistical inferences applied to the data shown in TABLE 1 (patients' ages, satisfaction rate of the physician, the patients and the blind-evaluator)

Descriptive variable	age	Satisfaction		
		Physician	Patients	Blind-evaluator
Mean	35,3	7,6	7,8	6,8
Median	32	8	8	7
Standard deviation	11,0	0,5	1,1	1,1
Variation coefficient	31%	7%	14%	16%
1 st quartile (Q1)	26	7	7	6
3 rd quartile (Q3)	47	8	9	8
Min	24	7	6	5
Max	51	8	9	8
N.	10	10	10	10
Confidence Interval	7,2	0,3	0,7	0,7

Clinical results are evident and important (Illustration 1). Such cutaneous benefits are possible thanks to the great capacity of the thiolic group to chelate iron, which even in a systemic use setting shows the capacity to avoid iron deposits on the spleen, and demonstrates an important antioxidant capacity in animals ⁹⁻¹¹.

The analysis of the pictures by the blind-evaluator dermatologist confirmed the efficacy of the 10% thioglycolic acid series of peelings; the improvement was evident even for a professional who did not take part in the application sessions.

This is the first report of the clinical benefits of using 10% thioglycolic acid serial peelings in the treatment of residual periorbicular hyperchromia. In addition to advising that this therapy is useful in the treatment of hemosiderotic dyschromias, this study has demonstrated that thioglycolic acid is a clinically safe, efficient, fast-acting and cost efficient product ^{7,11}.

From the clinical aesthetic responses obtained from study subjects, it can be deduced that the substance damages the epidermis, removing deposits of excess pigment. Furthermore, since the skin in the area is extremely thin, the damage caused is controlled and followed by the liberation of cytokines and inflammatory mediators (capable of providing the thickening of the epidermis), the deposit of collagen, the reorganization of the

structural elements and the increase of the dermal volume. Probable consequences include a reduction in the shading due to flaccidity and cutaneous sagging, and a decrease in the atrophy of the skin that causes the superficial vascular plexus to be visible.

The set of observed clinical results not only reduced hyperchromia, but also, as seen in Illustration 1, caused a significant improvement in the cosmetic aspect of the area, with the reduction of fine lines and cutaneous atrophy (the appearance of cigarette paper).

CONCLUSION

The serial and progressive application of 10% thioglycolic acid was demonstrated to be a safe, efficient and cost effective treatment of constitutional periorbicular hyperchromia. Yet this is not the only – or a miraculous – treatment for this condition; other therapies are also of paramount importance and could be used in combination with the study gel to affect even more improvement. It is also important to note that that changes in patient habits – including diet, smoking, exercise, and sleep patterns – are still important for a dermatologist to consider at the outset of any therapeutic plan. ●

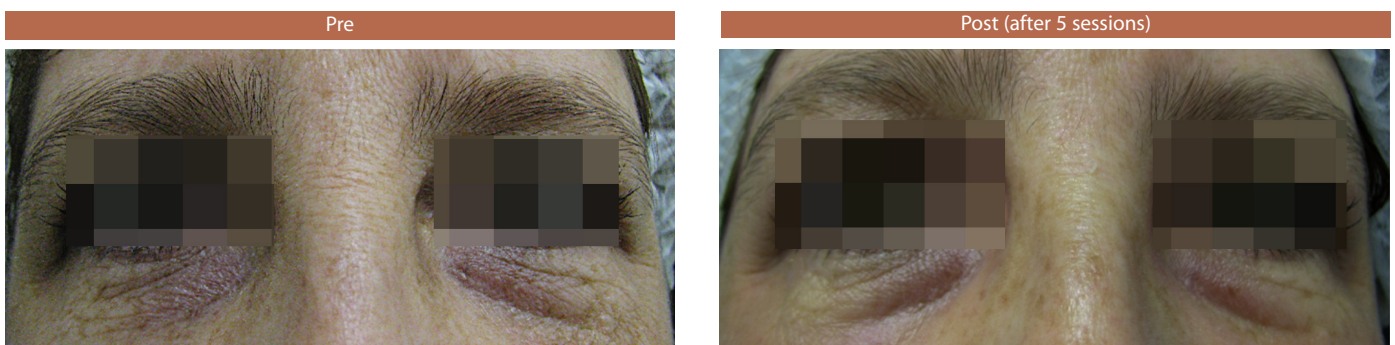


Figure 1: Pictures of one of the patients in the pre and post 10% thioglycolic acid gel peelings in constitutional infraorbital hyperchromia

REFERENCES

1. Malakar S, Lahiri K, Banerjee U, Mondal S, Sarangi S. Periorbital melanosis is an extension of pigmentary demarcation line-F on face. *Indian J Dermatol Venereol Leprol.* 2007;73(5):323-5.
2. Sampaio S, Rivitti E. *Dermatologia.* 3 ed. Artes Médicas: São Paulo; 2007.
3. Lowe NJ, Wieder JM, Shorr N, Boxrud C, Saucer D, Chalet M. Infraorbital pigmented skin. Preliminary observations of laser therapy. *Dermatol Surg.* 1995; 21(9):767-70.
4. West TB, Alster TS. Improvement of infraorbital hyperpigmentation following carbon dioxide laser *resurfacing.* *Dermatol Surg.* 1998;24(6):615-6.
5. Mitsuishi T, Shimoda T, Mitsui Y, Kuriyama Y, Kawana S. The effects of topical application of phytonadione, retinol and vitamins C and E on infraorbital dark circles and wrinkles of the lower eyelids. *J Cosmet Dermatol.* 2004;3(2):73-5.
6. Khunger N; IADVL Task Force. Standard guidelines of care for chemical peels. *Indian J Dermatol Venereol Leprol.* 2008;74 (Suppl):S5-12.
7. Tulli R, Izzo M. El papel del ácido tioglicólico em las pigmentaciones férricas. *Rev Panam Flobol Linfol.* 2001;41(2):57-63.
8. Burnett CL, Bergfeld WF, Belsito DV, Klaassen CD, Marks JG Jr, Shank RC, et al. Final amended report on the safety assessment of Ammonium Thioglycolate, Butyl Thioglycolate, Calcium Thioglycolate, Ethanolamine Thioglycolate, Ethyl Thioglycolate, Glycerol Thioglycolate, Isooctyl Thioglycolate, Isopropyl Thioglycolate, Magnesium Thioglycolate, Methyl Thioglycolate, Potassium Thioglycolate, Sodium Thioglycolate, and Thioglycolic Acid. *Int J Toxicol.* 2009;28(4 Suppl):68-133.
9. Joo MS, Tourillon G, Sayers DE, Theil EC. Rapid reduction in horse spleen ferritin by thioglycolic acid. *Bio Met.* 1990;3(3-4):171-5.
10. Hoffman U, Eichelbaum M, Seefried S, Meese CO. Identification of thioglycolic acid, thiodiglycolic acid sulfoxide, and (3-carboxymethylthio) lactic acid as major human biotransformation products of S-carboxymethyl-L-cysteine. *Drug Metabol Dispos.* 1991;19(1):22-6.
11. Goldman N, Neto B, Goldman K. Tratamento das Hiperpigmentações de Membros Inferiores Desencadeadas pela Insuficiência Venosa com o Uso de Ácido Tioglicólico. [acesso 05 jun 2009]. Disponível em: www.sbme.org.br/portal/download/revista/14/04_Tratamento_das_Hiperpigmentacoes.pdf