

# Posterior cerebrocerebellar connections: Türck's bundle and tractography

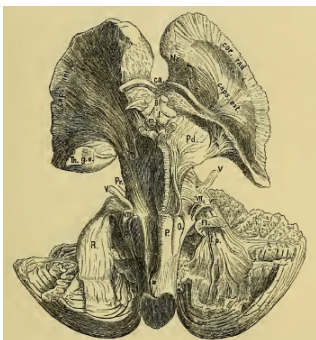## *Conexões cérebro-cerebelares posteriores: feixe de Türck e tratografia*

Elias Engelhardt<sup>1</sup>, Denise Madeira Moreira<sup>2</sup>

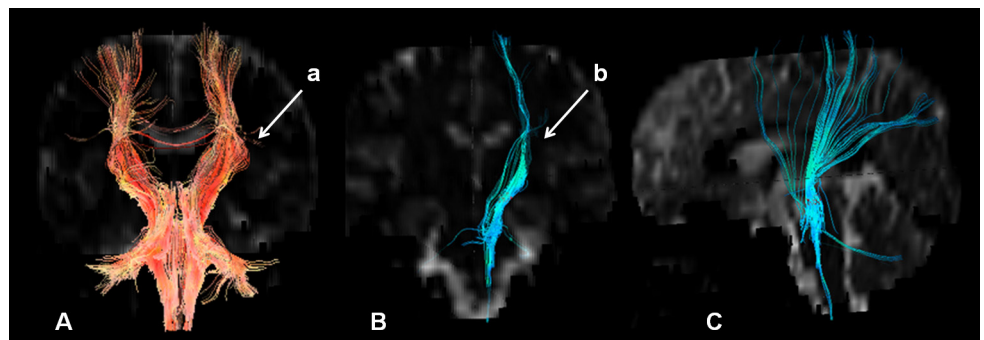
The cerebellum, traditionally considered as a structure related to balance and movement control, is engaged also in cognitive and affective activities. Neuroanatomic studies of the cerebrocerebellar system have disclosed anterior, from the prefrontal cortex (Arnold's bundle), and posterior projections, from parieto-occipito-temporal areas (Türck's bundle), to the pons. This assemble of fibers, which traverse the lateral part of the cerebral peduncles, originating in the cerebral cortex and ending in the pons, was first described (1874), and later dissected and

named for Türck (1884), by Theodor Hermann Meynert (1833–1892)<sup>1</sup>. He provided (1884) a clear macrodissection and description of the tract (Figure 1)<sup>2</sup>.

Advanced neuroimaging with diffusion tensor and tractography has permitted virtual dissection of white matter tracts, including cerebellar ones, in vivo<sup>3</sup>. The first studies of the bases for this technique appeared in 1992, and virtual dissection was implemented in the following years<sup>4</sup>. A tractographic study of Türck's bundle is here presented (Figure 2).



**Figure 1.** Meynert's "real dissection" of the human diencephalon, brainstem and cerebellum (basal view) (Figure 22, p 47): Pd=peduncular foot, Tm=temporal radiation of the "fan-shaped bundle originated from the temporal and occipital lobes" (or Türck's bundle)<sup>2</sup>.



**Figure 2.** Türck's bundle tractography- a "virtual dissection": A=corona radiata tracts at the level of the internal capsule and brainstem (arrow a – external fibers – corresponding to Türck's bundle); B=tractogram of left Türck's bundle (blue) (arrow b) in coronal view; C=the same tractogram in sagittal view (adapted from Engelhardt and Moreira - with permission of the RBN [2008;44(4):19-34, 2009;45(3):17-27, and 46(1):39])

## REFERENCES

- Engelhardt E. Cerebrocerebellar System and Türck's Bundle. *Journal of the History of the Neurosciences* 2013;22(4):353-365.
- Meynert TH. *Psychiatrie. Klinik der Erkrankungen des Vorderhirns*. Wien: W. Braumüller, 1884, p 40. [Retrieved from: <http://www.archive.org/details/tails/psychiatrieklini00meyn>]
- Engelhardt E, Moreira DM, Laks J. Cerebrocerebellar System - Türck's Bundle Tractography. Preliminary Results. Poster presented at the 6<sup>th</sup> International Congress on Vascular Dementia, Barcelona, 2009.
- Catani M, de Schotten MT. A diffusion tensor imaging tractography atlas for virtual in vivo dissections. *Cortex* 2008;44:1105-1132.

<sup>1</sup>Cognitive and Behavioral Neurology Unit – INDC/CDA-IPUB-Institute of Psychiatry - UFRJ;

<sup>2</sup>Neuroradiology Unit - INDC/UFRJ; Radiology Service PróCardíaco Hospital-Rio de Janeiro

**Endereço para correspondência:** e-mail: eliasz@centroin.net.br