

Avulsion and replantation of permanent incisive: 13 years of control

Gláucia Beatriz **GONÇALVES**^{1,3}
 Aline Thomazelli Peres **TOMAZOLI**²
 Lilian Vessoni **IWAKI**^{2,4}
 Marcos Sérgio **ENDO**^{2,5}
 Nair Narumi Orita **PAVAN**^{2,6}

DOI: <https://doi.org/10.14436/2358-2545.9.1.058-064.oar>

ABSTRACT

Introduction: The maintenance of a traumatized tooth in the oral cavity depends on a correct emergency treatment, as well as a long and adequate period of clinical-imaging follow-up. **Objective:** To report a clinical case of avulsion and replantation of tooth 11, in an 11-year-old child, who has been in the oral cavity for 13 years. **Methods:** tooth replantation 45 minutes after avulsion, endodontic treatment with 10 monthly exchanges of intracanal calcium hydroxide medication, followed by root canal filling using lateral condensation technique. Clinical and radiographic follow-up.

Results: after 13 years of clinical and imaging control, tooth 11 presents aesthetically satisfactory function. **Conclusion:** The upper right central incisor, avulsed, replanted and ankylosed presented an evolutionary condition of root resorption by substitution, but inactive until the last follow-up. After endodontic treatment and clinical and imaging follow-up, the tooth remained in the oral cavity in function, without symptomatology and aesthetically pleasing after 13 years of replantation.

Keywords: Tooth Avulsion. Endodontics. Tooth Replantation.

How to cite: Gonçalves GB, Tomazoli ATP, Iwaki LV, Endo MS, Pavan NNO. Avulsion and replantation of permanent incisive: 13 years of control. *Dental Press Endod.* 2019 Jan-Apr;9(1):58-64.
 DOI: <https://doi.org/10.14436/2358-2545.9.1.058-064.oar>

» The authors report no commercial, proprietary or financial interest in the products or companies described in this article.

» Patients displayed in this article previously approved the use of their facial and intraoral photographs.

¹Universidade Estadual de São Paulo, Faculdade de Odontologia de Bauru, Programa de Pós-Graduação em Ciências Odontológicas (Bauru/SP, Brazil).

²Universidade Estadual de Maringá, Departamento de Odontologia (Maringá/PR, Brazil).

³Master's degree in Endodontics, Universidade de São Paulo, Faculdade de Odontologia de Bauru (Bauru/SP, Brazil).

⁴Doctorate degree in Dental Radiology and Imaging, Universidade de Campinas, Faculdade de Odontologia de Piracicaba (Piracicaba/SP, Brazil).

⁵Doctorate degree in Dental Clinic, Endodontics area, Universidade de Campinas, Faculdade de Odontologia de Piracicaba (Piracicaba/SP, Brazil).

⁶Doctorate degree in Pharmacology, Endodontics area, Universidade Estadual de Maringá (Maringá/PR, Brazil).

Submitted: September 16, 2017. Revised and accepted: November 07, 2017.

Contact address: Gláucia Beatriz Gonçalves
 E-mail: glauciabg1993@gmail.com - glauciabg@usp.br

Introduction

Dental trauma in children and adolescents is a public health problem that can result in functional, aesthetic and psychological disorders. Its prevalence has increased significantly in recent years and its incidence may exceed that of dental caries and periodontal diseases.^{1,2}

The buccal cavity is the fourth most common area of body lesions between 7 and 30 years of age and, among the facial lesions, the dental ones are the most common.^{1,3} The avulsion of permanent teeth presents a frequency of 0.5% to 16% among dental traumas and represents one of the few real situations of dental emergence.⁴

The treatment for avulsion, in most cases, consists of immediate replantation; however, it will not be indicated in special situations, such as in the presence of severe caries lesions, periodontal disease, non-cooperating, unconscious or immunosuppressed patients³. The prognosis will depend mainly on the measures taken at the accident site, the avulsed tooth transport medium and the time taken for the replantation, followed by the evaluation and follow-up of the dental surgeon (DS)^{3,5,6}. The success of the procedure is directly related to the maintenance of the vitality of the periodontal ligament of the avulsed teeth.^{7,2,8} The replantation can save the tooth, but it should be emphasized that in certain situations the chances of success are lower, and even the loss of the dental element may occur.³

Periodic evaluations should be performed for at least 5 years, since pathological changes may occur in the adjacent teeth, long after the initial accident.⁵

Reports of follow-ups of cases of avulsion for more than a decade are scarce in the literature.^{9,4,10,11,12} In view of this, we present a case of successful replantation of a permanent upper central incisor in an 11-year-old boy, with clinical and imaging follow-up of 13 years.

Case report

Male patient, 11 years old, suffered avulsion of the upper right central incisor (11) after being hit by car. The tooth was stored dry until the arrival at the hospital. During the care, it was immersed in saline before replantation and soft tissue suture, 45 minutes after the trauma.

After undergoing clinical and radiological examinations, coronary fracture of the teeth 21 and 11 was also diagnosed (Fig 1), and tooth 11 presented mobility and sensitivity to palpation and percussion. The non-rigid splinting of the teeth 12, 11, 21 and 22 was performed with nylon thread and composite resin.

After 15 days, the endodontic treatment of the replanted tooth started, which was the only element that responded negatively to the cold sensitivity test with Endo-Ice -50° (Maquira, Paraná, Brazil). Medications with Formocresol (Biodinâmica, Paraná, Brazil) (Fig 2) and radiographic odontometry (Fig 3) were performed. In the second visit, root canal instrumentation was performed by the crown-apex technique, using flexofile manual files (DentsplyMaillefer, Ballaigues, Switzerland), obtaining the memory file K#80, with irrigation of 1% Sodium Hypochlorite (Asfer); application of Trisodium EDTA (Biodinâmica, Paraná, Brasil) for three minutes; intracanal medication with Callen paste (SSWhite), and restoration with temporary cement Coltosol (Coltene-Vigodent, Rio de Janeiro, Brazil) (Fig 4).

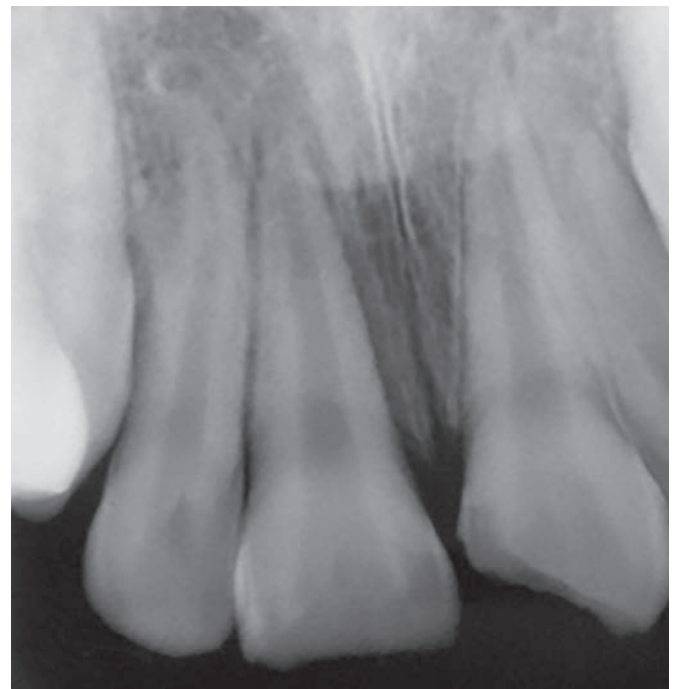


Figure 1. Initial periapical radiography.

Thirty days after trauma, splint was removed and a new cold sensitivity test was performed, in which teeth 12, 21 and 22 responded positively. After 45 days, the class IV restoration of element 11 was made with Opallis composite resin (FGM, Santa Catarina, Brazil). There were 10 exchanges of intracanal medication with Callen paste, with an average interval of 60 days between them. The medication substitutions occurred due to the diagnosis of root resorption by substitution, in an attempt to decrease osteoclastic activity.

The root canal filling (Figs 5, 6 and 7) was based on the technique of lateral condensation, using gutta-percha cones (Tanari, Amazon, Brazil) and Endofil

cement (DentsplyMaillefer, Ballaigues, Switzerland).

After 8 years, the patient underwent orthodontic treatment. In this period, tooth 11 was ankylosed and with inactive root resorption.

At the control visit, twelve years after trauma, periapical radiography, Cone Beam tomography (I-Cat Next Generation) (Fig 8), intraoral images (Figs 10 and 11), palpation tests, vertical and horizontal percussion were performed with the handle of the intraoral mirror and cold sensitivity in teeth 12, 21 and 22, that responded positively, with absence of symptomatology and mobility.

In 2016, thirteen years after the accident, the clinical condition remained stable (Figs 9, 10, 11).

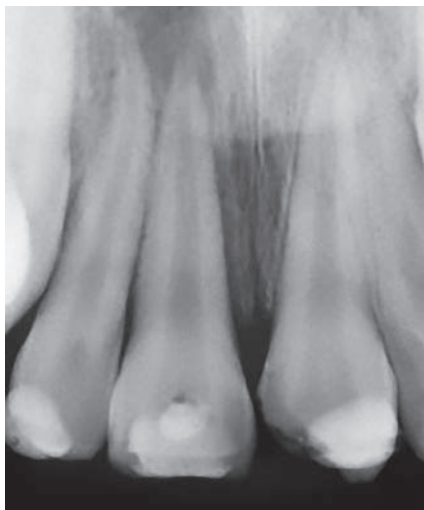


Figure 2. Intracanal medication.

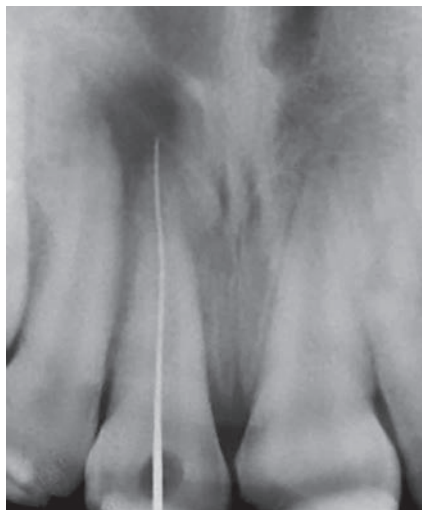

Figure 3. Odontometry.

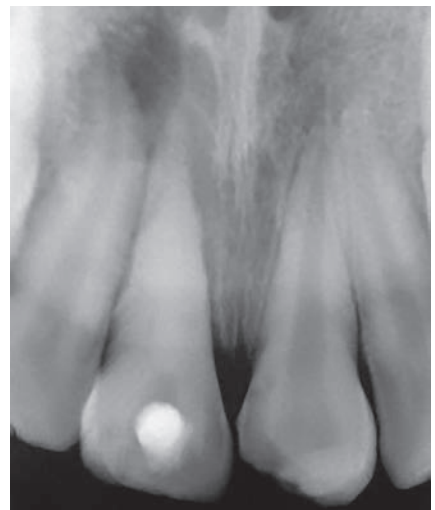

Figure 4. Intracanal medication.

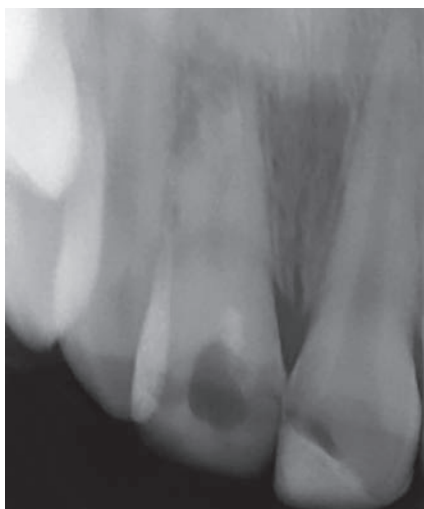


Figure 5. Periapical tooth 11.

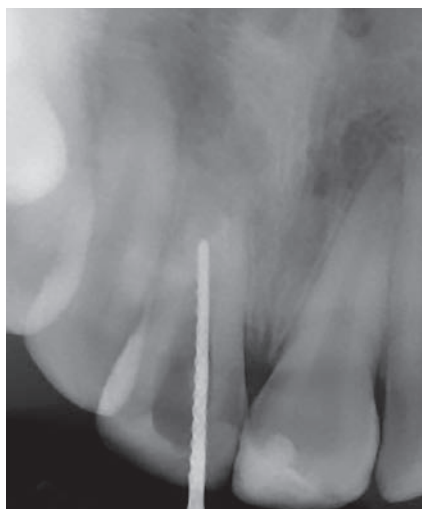

Figure 6. Cone test.

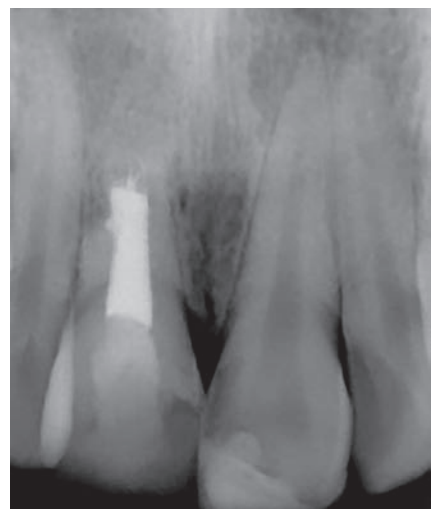

Figure 7. Filling.

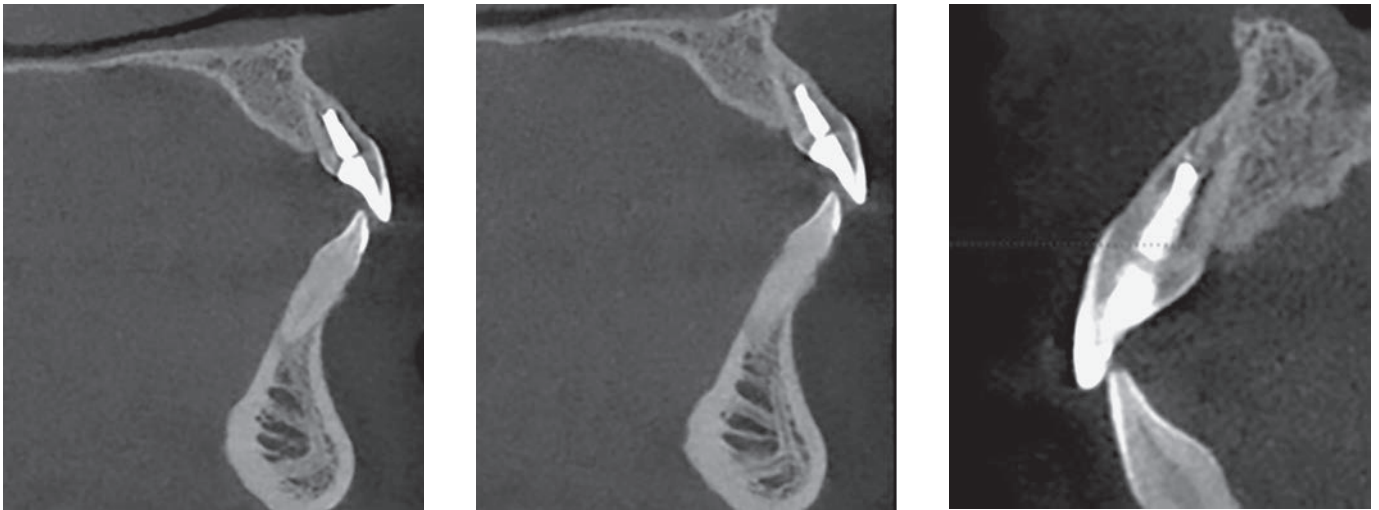


Figure 8. Cone Beam Sagittal sections, July 2015.

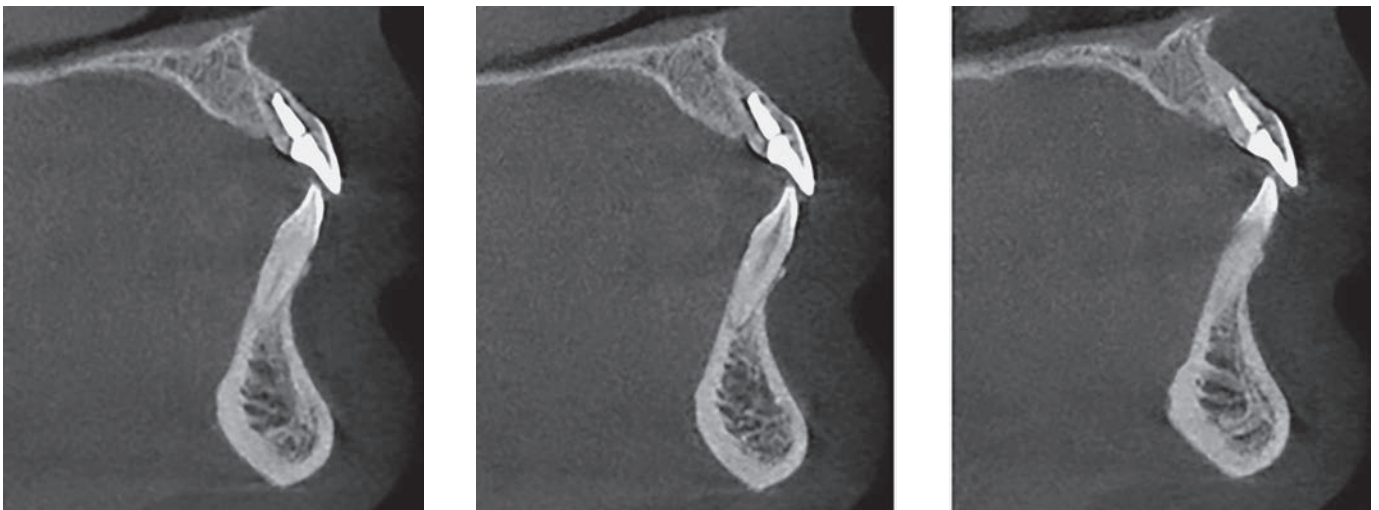

Figure 9. Cone Beam Sagittal sections, November 2016.

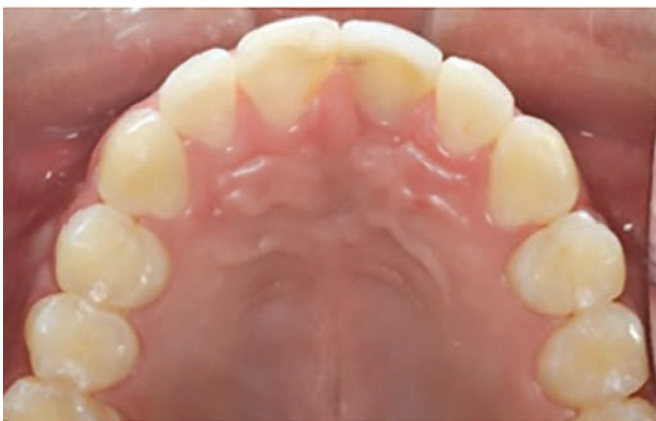

Figure 10. Occlusal view.

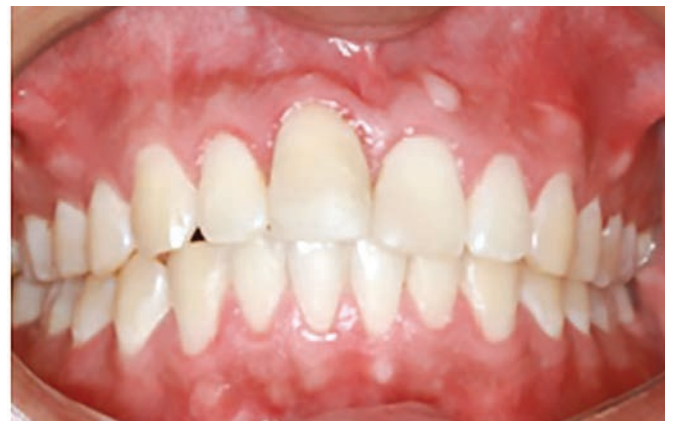

Figure 11. Frontal view.

Discussion

The treatment of choice proposed in the literature for cases of avulsion of permanent teeth is the replantation, since it allows the preservation of the alveolar bone structure and the survival of the dental element, even for an indeterminate period, enabling the patient, especially as a child and adolescent, to maintain the natural tooth until the moment of the placement of a prosthesis and/or implant.¹³ In addition, replantation rehabilitation will favor restoration of the patient's aesthetic, functional and psychological factors.^{3,14}

However, the prognosis depends on the actions taken at the accident site, immediately after the trauma, considering in addition to other issues, extra-oral time, storage and manipulation of the tooth and the technique performed for the treatment, always aiming at the maintenance of the periodontal ligament cells.^{4,15} When replanted up to 30 minutes after avulsion, there is a 90% chance of success; however, after 2 hours, the chance of success decreases to approximately 5%.¹⁵

It is necessary to pay attention to questions such as replanting only permanent teeth, holding them exclusively by the crown, washing in cold running water for about 10 seconds and performing the replantation. If this is not possible, store the tooth in liquids, preferably in special media, such as cell culture media and Hanks' balanced solution, or else milk, saline or saliva. Storage in water should be avoided because a hypotonic environment causes rapid cell lysis and may increase inflammation after replantation.^{3,16}

Systemic administration of antibiotics after replantation is a recommended conduct; however, its value is questionable, especially when the general health of the patient does not justify it.³ Experimental studies, however, generally show positive effects in relation to periodontal and pulpal repair, especially when administered topically and in cases of incomplete rhizogenesis. It is recommended to immerse the tooth for 5 minutes in the minocycline or doxycycline solution, 1mg per 20mL saline.¹⁶

The tetanus vaccine should be recommended to the patient who was not previously immunized if the avulsed tooth had contact with the ground.³

Specifically, in this case, the patient was in perfect health and properly vaccinated against tetanus.

He was taken to the hospital with his tooth avulsed in a dry environment, remaining in this way for about 45 minutes. In dry environments, the chances of the cells of the periodontal ligament (PLC) remaining vital are very low.^{16,17} After an extra-alveolar time of 60 minutes or more, all these cells will be inviable; if the tooth is replanted immediately, they will probably be viable and, if the tooth is kept in correct storage medium and the total extra-alveolar time was less than 60 minutes, the PLC may be viable but impaired.³

Therefore, in the patient in question, there was possibility of impaired PLC and probably inviable, since the replantation time was 45 minutes, with the tooth stored unsatisfactorily. The family was informed of the possibilities of an unfavorable prognosis, with the possible loss of the dental element. Studies reporting this consequence are common, including ankylosis and resorption by substitution.^{14,8}

In this case, ankylosis was unavoidable, due to the involvement of the PLC of tooth 11. Consequently, a severe inflammatory response was generated in a large root area, allowing the occurrence of resorption by substitution. This occurs as slower cementoblasts cannot cover the entire root surface in time and odontoblasts directly join the root surface in an attempt to repair, thus gradually replacing the root with bone. Over time, the whole root can be replaced.¹⁸

Root resorptions are found in 63% of replanted teeth. Ankylosis, followed by root resorption by substitution, accounts for 41% of all cases of resorption.¹⁹

Pulp necrosis represents another sequel of dental avulsion, where necrotic tissue becomes extremely sensitive to bacterial contamination.^{13,2} The combination of cement damage on the outer surface of the root and bacterial contamination in the root canal favors the future appearance of inflammatory root resorption, which makes endodontic therapy indispensable.^{20,18} In this case, it was started 15 days after the trauma, as a consequence of confirmation of pulpal necrosis (Fig 6).

Endodontic treatment in avulsed teeth with complete rhizogenesis should occur 7 to 10 days after replantation; however, if the extra-alveolar time was greater than 60 minutes, it may occur before being replanted. In the case of a tooth with incomplete rhizogenesis, the purpose of the replantation is to allow

a possible pulp revascularization, provided that it occurs immediately after the trauma, or with extra-alveolar time less than 60 minutes, however, if the time is longer than this, endodontic treatment should be performed before or after replantation.¹⁶

Replanted teeth require periodic clinical and radiographic monitoring after 4 weeks, 3 months, 6 months, 1 year and thereafter annually for long term;^{2,21} however, reports of cases describing follow-up for more than 4 or 5 years are not common.^{22,9,15,16}

The longest-lasting follow-up found in the literature, and therefore the ideal, is a case with 27 years of clinical and imaging follow-up, with replantation after 30 minutes.⁹ The scarcity of these reports can be attributed to reasons such as early loss of the replanted tooth, lack of information from professionals and lay people on how to act in cases of avulsion and lack of patient follow-up.

During the follow-up period, the patient started orthodontic treatment with another professional (Fig 8). Avulsion and replantation do not contraindicate it, provided that clinical and radiographic observations of the repair and/or post-trauma complications are performed before and during treatment. Nevertheless, the ankylosed tooth is not moveable, and may remain in the arcade as a space maintainer indefinitely, depending on the progression of the substitutive resorption.¹³

The case treated here showed in its last control, through periapical radiography, Cone Beam tomography, and clinical tests, element 11 with inactive root resorption, in occlusion and aesthetically satisfactory.

Conclusions

In view of the clinical practices found in the literature and the one performed in the present case, we can conclude that the procedures adopted were satisfactory, even if the replantation has taken more than 30 minutes to take place with the tooth stored in a dry medium, since the purpose was, besides rehabilitating the tooth for aesthetic, functional and psychological reasons, the maintenance of the alveolar bone contour.

The upper right central incisor, avulsed, replanted and ankylosed presented an evolutionary condition of root resorption by substitution, but inactive until the last follow up. After endodontic treatment with periodic changes of intracanal medication based on calcium hydroxide and clinical and imaging follow-up, the tooth remained functional in the buccal cavity, without symptoms and aesthetically pleasing after 13 years of replantation.

Periodic follow-ups of long periods of trauma patients are important for a satisfactory evolution of the case. However, studies with more than a decade of preservation are rare in the literature.

References

1. Rajab LD. Traumatic dental injuries in children presenting for treatment at the Department of Pediatric Dentistry, Faculty of Dentistry, University of Jordan, 1997-2000. *Dent Traumatol.* 2000;19(1):6-11.
2. Manfrin TM, Boaventura RS, Poi WR, Panzarini SR, Sonoda CK, Massa Sundefeld ML. Analysis of procedures used in tooth avulsion by 100 dental surgeons. *Dent Traumatol.* 2007;23(4):203-10.
3. Flores MT, Andersson L, Andreasen JO, Bakland LK, Malmgren B, Barnett F, et al. Guidelines for the management of traumatic dental injuries. II. Avulsion of permanent teeth. *Dent Traumatol.* 2007 June;23(3):130-6.
4. Davidovichi E, Moskoritz M, Moskoritz J. Replantation of an immature permanent central incisor following pre-eruptive traumatic avulsion. *Dent Traumatol.* 2008;24(5):47-52.
5. Trope M. Clinical management of the avulsed tooth: present strategies and future directions. *Dent Traumatol.* 2002;18(1):1-11.
6. Traebert J, Traiano ML, Armênio R, Barbieri DB, de Lacerda JT, Marcenés W. Knowledge of lay people and dentists in emergency management of dental trauma. *Dent Traumatol.* 2009;25(3):277-83.
7. Kenny DJ, Barrett EJ. Recent developments in dental traumatology. *Pediatr Dent.* 2001 Nov-Dec;23(6):464-8.
8. Soares AJ et al. Relationship between clinical - radiographic evaluation and outcome of teeth replantation. *Dent Traumatol.* 2008;24(2):183-8.
9. Martins WD, Westphalen VP, Westphalen FH. Tooth replantation after traumatic avulsion: a 27 - year follow up. *Dent Traumatol.* 2004;20(2):101-5.
10. Koca H, Topaloglu-Ak A, Süttekin E, Koca O, Acar S. Delayed replantation of an avulsed tooth after 5 hours of storage in saliva: a case report. *Dent Traumatol.* 2010;26(4):370-3.
11. Misra SB, Tumba KJ. Case report: a combined avulsion and root fracture/avulsion trauma with ten years review. *Eur Arch Pediatr Dent.* 2008;9(3):153-9.
12. Day PF, Duggal MS, High AS, Robertson A, Gregg TA, Ashley PF, et al. Discoloration of teeth after avulsion and replantation: results from a multicenter randomized controlled trial. *J J Endod.* 2011 Aug;37(8):1052-7.
13. Rocha SRT, Moro A, Moresca RC, Sydney G, Fraiz F, Baratto Filho F. Orthodontic treatment in patients with reimplanted teeth after traumatic avulsion: A case report. *Dental Press J Orthod.* 2010;15(4):40.e1-10.
14. Treatment of the avulsed permanent tooth. Recommended guidelines of the American Association of Endodontists. *Dent Clin North Am.* 1995 Jan;39(1):221-5.
15. Qazin SR, Nasir KS. First-aid knowledge about tooth avulsion among dentists, doctors and lay people. *Dent Traumatol.* 2009;25(3):295-9.
16. Andersson L, Andreasen JO, Day P, Heithersay G, Trope M, DiAngelis AJ, et al. Guidelines for the management of traumatic dental injuries: 2. Avulsion of permanent teeth. *Pediatr Dent.* 2016 Oct;38(6):369-76.
17. Andreasen JO, Borum MK, Jacobsen HL, Andreasen FM. Replantation of 400 avulsed permanent incisors. 4. Factors related to periodontal ligament healing. *Endod Dent Traumatol.* 1995;11(2):76-89.
18. Trope M, Friedman S. Periodontal healing of replanted dog teeth stored in Viaspan, milk and Hank's balanced salt solution. *Endod Dent Traumatol.* 1992;8(5):183-8.
19. Gulinelli JL, Saito CT, Garcia-Júnior IR, Panzarini SR, Poi WR, Sonoda CK, et al. Occurrence of tooth injuries in patients treated in hospital environment in the region of Araçatuba, Brazil during 6 years period. *Dent Traumatol.* 2008;24(6):640-4.
20. Tzigkounakis V, Merglová V, Hecová H, Netolický J. Retrospective clinical study of 90 avulsed permanent teeth in 58 children. *Dent Traumatol.* 2008;24(6):598-602.
21. Petrovic B, Marković D, Peric T, Blagojevic D. Factors related to treatment and outcomes of avulsed teeth. *Dent Traumatol.* 2010;26(1):52-9.
22. Zhang X, Gong Y. Characteristics of avulsed permanent teeth treated at Beijing Stomatological Hospital. *Dent Traumatol.* 2011;27(5):379-84.