

# POSSIBLE PROTECTIVE EFFECT OF OLIVE LEAVES EXTRACT ON PARACETAMOL INDUCED HEPATOTOXICITY IN MALE ALBINO RATS

## *POSSÍVEL EFEITO PROTETOR DO EXTRATO DE FOLHAS DE OLIVEIRA NA HEPATOTOXICIDADE INDUZIDA POR PARACETAMOL EM RATOS ALBINOS MACHOS*

Mervat El Sayed TAHA<sup>1</sup>; Amaal Mohamed KAMAL<sup>1</sup>; Dalia Ramzy IBRAHIM<sup>1</sup>

1. Biological Applications Department, Nuclear Research Center, Atomic Energy Authority, Cairo, Egypt  
Mervattaha12@gmail.com

**ABSTRACT:** Paracetamol (PCM) overdose can cause hepatotoxicity with oxidative stress; the present study was carried out to establish the possible protective effect of olive leaves extract (OLE) on toxicity induced by paracetamol in adult male rats. Twenty four adult male rats were divided into four equal groups; control, olive leaves extract group, paracetamol group and olive leaves extract plus paracetamol group. Some biochemical parameters and liver histopathology were evaluated. PCM treatment significantly increased serum aspartate aminotransferase (AST), alanine aminotransferase (ALT), total bilirubin, gamma-glutamyltransferase (GGT), lactate dehydrogenase (LDH), urea, creatinine and alpha-fetoprotein. Paracetamol was found to significantly increase malonaldehyde (MDA) and decrease glutathione reductase (GR) activity in tissue and significantly decrease total antioxidant capacity (TAC) and superoxide dismutase (SOD) in serum. Administration of OLE caused a significant decrease serum AST, ALT enzyme, total bilirubin, GGT, LDH, creatinine, urea, alpha-fetoprotein. Also, amelioration of oxidant – antioxidant status with olive leaves extract was observed in addition to a significant decrease in MDA and a significant increase in TAC in liver tissue with a significant increase in glutathione reductase (GR) and SOD in serum compared to paracetamol treated group. The chemical pathological changes were in step with histopathological observation suggesting marked hepatoprotective result of olive leaves extract. It could be concluded that olive leaves extract (OLE) treatment may be effective in decreasing hepatic injury and oxidative stress induced by paracetamol overdose in male albino rats

**KEYWORDS:** Paracetamol. Olive leaves extract. Liver enzymes. Oxidant - antioxidant status.

### INTRODUCTION

Liver is one of the most important organs in the body that functions as a center for metabolism of nutrients such as carbohydrates, proteins, and lipids. It is also involved in the metabolism and excretion of waste metabolites and drugs, thereby providing protection against foreign substances by detoxifying and eliminating them (MOHAMED-SALEEM et al., 2010). Hepatotoxicity occurs due to drugs steroids, vaccines, antiviral and other medications (SEHRAWAT et al., 2006; RUSSMANN; KULLAK-UBLICK; GRATAGLINO, 2009).

Paracetamol is widely used as antipyretic. It is a safe drug when given in therapeutic doses, but its overdose can lead to acute liver damage in humans. The hepatotoxicity of paracetamol has been attributed to the formation of toxic metabolites when a part of paracetamol is activated by hepatic cytochrome P-450 (DAS et al., 2010) to a highly reactive metabolite N-acetyl-P-benzoquinoneimine (NAPQI), which in turn, binds covalently to tissue

macromolecules, thereby causing severe hepatic damage.(KIM et al., 2009; KUMAR; RAMESH; MOHAN, 2014). Nephrotoxicity is less common than hepatotoxicity in PCM overdose, renal tubular damage and acute renal failure can occur even in the absence of liver injury (CHINNAPPAN et al.,2019 )

Herbal drugs play a role in the management of various liver disorders most of which speed up the natural healing processes of the liver (SUBRAMONIAM et al., 1988). The olive tree (*Olea europaea* L.) family: Oleaceae is commonly used as a part of traditional herbal medicine to treat disease in the Mediterranean area (HAKEMI et al., 2019). Phytoconstituents such as flavonoids, glycosides, triterpenoids, carbohydrates, steroids, polyphenols present in OLE revealed various therapeutic potentials against many diseases including diabetes , wounds , fever, , gout, atherosclerosis, and hypertension (WANG et al., 2008; AL-BASHER 2018).

The purpose of this work was to clarify the hepatoprotective and antioxidant role of olive leaves extract on paracetamol overdose effect in male rats.

## MATERIAL AND METHODS

### Drugs

Panadol (paracetamol) (500mg) was purchased from Alexandria Company for Pharmaceuticals and Chemicals Industries under License: GlaxoSmithkline Consumer Healthcare Ltd. Ireland

### Collection and preparation of olive leaves extraction

Olive leaves were collected from a local field cultivated by Oleaeuropaea at Nuclear Research Center, Egyptian Atomic Energy Authority, Inshas, Egypt

### Extraction procedure

Extraction process was performed according to Sahin and Samli (2013). One thousand grams of

fresh Leaves were washed by running tap water then rinsed by distilled water after drying, leaves were crushed to fine powder, they were soaked in water: ethanol (1:1, v: v) for 48 hours, then filtered through Whatman No. 1 filter paper under reduced pressure. The filtrate was extracted by an equal volume of methylene chloride three times. The methylene chloride layer was separated by a separating funnel. The collected methylene chloride layers were filtered over anhydrous sodium sulfate and then evaporated under vacuum until dryness using rotary evaporator (IKA, RV10, Germany). The dried crude extract (approximately 18 gm) was dissolved in water to the desired concentrations and stored at 7°C.

### Preliminary phytochemical analysis

Gas chromatography- mass spectrometry (GC / MS) analysis of olive leaves extract was performed and revealed the presence of many bioactive compounds (Table 1).

**Table 1.** Chemical analysis of olive leaves extract

<i>NO</i>	<i>RT</i>	<i>Name</i>	<i>Area Sum%</i>
1	10.4	α-Santonin	3.79
2	11.49	Heptadecanoic acid	2.8
3	12.28	6-epi-shyobunol	2.45
4	12.63	1,4-Methanoazulen—7-ol,decahydro-1,5,5,8a-tetramethyl-,[1s-1α,3AB,4α,7B,8aB]	2.47
5	12.87	Neophytadiene	1.66
6	13.06	Phytol,acetate	0.54
7	13.227	Phytol	0.95
8	13.46	Nobiletin	1.2
9	13.72	Stearic acid(Octadecanoic acid)	13.14
10	14.48	Rhodopin	2.84
11	14.78	Cis-Vaccenic acid 11E-Octadec-11-enoic acid	15.22
12	14.92	Arachic acid	4.16
13	15.56	Stigmasterol	4.09
14	16.44	B-Sitosterol	4.69
15	16.8	Isovitexin	5.07
16	17.8	5-Pregnen-3B-Ol-2O-one	5.5
17	19.07	γ-Tocotrienol	2.12
18	19.45	Desmosterol	2.02
19	20.6	Phytanic acid	0.84
20	21.71	Mangiferin	4.08
21	21.86	Myristoleic acid	7.68
22	21.97	Astilbin	7.09
23	22.65	Quercetin 3-methyl ether	2.15
24	22.9	Pentadecanic acid,14-methyl-	3.45

### Experimental animals

Twenty four (24) adult male Wister albino rats, weighing 150 to 200 g, were used for the study. All animals were obtained from the animal house of Radiobiological Applications Department, Nuclear Research Center. Atomic Energy Authority, Egypt. They were fed on standard rat diet and water. The study was conducted in accordance with the guidelines set by CIOHS& ICLAS International Guiding Principles for Biomedical Research involving animals(2012) which is in accordance with the Guide for the Care and Use of Laboratory Animals (8<sup>th</sup> Edition, 2011, published by The National Academics Press, 2101 Constitution Ave, NW, Washington, DC20055, USA) This guide was approved by the Ethical committee at National Center for Radiation Research and Technology, Egyptian Atomic Authority, Cairo, Egypt(NCRRT-EAEA).

### Experimental design

The animals were randomly divided into four equal groups having (six rats each) Group, I served as a control and received orally a daily dose of 1ml normal saline for twelve successive days. Groups 2 and 4 were given olive leaves extract orally (150 mg/kg.b.wt.) According to Sarbishegi, Sarbishgi et al. (2017) in 1ml distilled water daily for twelve successive days.

On the 12<sup>th</sup> day, 1g/kg.b. wt paracetamol suspension in 1ml saline was given orally to rats of groups 3 and 4 according to McGill et al. (2012). The rats were fasted overnight and were euthanized by cervical dislocation on the thirteenth day.

### Biochemical studies

Blood was obtained from all animals. Serum was separated by centrifugation at 3000 rpm at 30°C for 15min, collected into sterilized tubes and stored at -20°C. Serum biochemical parameters were analyzed. The serum aspartate aminotransferase (AST), alanine aminotransferase (ALT), total bilirubin, alkaline phosphatase (ALP), gamma-glutamyltransferase ( $\gamma$ -GT) and lactate dehydrogenase (LDH) were determined using Spinreact kits (S.A.U. Ctra. Santa Coloma, Spain). Alpha-Fetoprotein ( $\alpha$ -FP) was determined using a rat radioimmunoassay kit (RIA), the Institute of Isotopes Co., Ltd. (IZOTOP). Hungary, according to Kroes et al., (1975). Total antioxidant capacity was determined using enzyme-linked immunosorbent assay kit (ELISA) (MyBioSource, San Diego, USA). Superoxide dismutase (SOD) was assayed according to the method of Kakkar et al. (1984).

### Preparation of liver homogenate

After the rats were euthanized, the livers were rapidly removed. 500mg of each liver was weighed and homogenized with 5 ml of 0.2M Tris-EDTA (PH. 8.0). The homogenate was used for the estimation of glutathione reductase (GR) activity, by the procedure adopted by David and Richard (1983) and the level of malondialdehyde (MDA) was measured according to the method of Ohkawa, Ohishi and Yagi (1979).

### Histopathological examination

Small pieces of liver tissues in each group were collected in 10% neutral buffered formalin for proper fixation. These tissues were processed and embedded in paraffin wax. Sections of 5-6  $\mu$ m in thickness were cut and stained with hematoxylin and eosin. These sections were examined for histopathological changes and photographed (BANCROFT; STEVEN; TURNER, 1996).

### Statistical analysis

The experimental data were analyzed by one-way ANOVA using Statistical Package for Social Sciences (SPSS) version 20. The mean difference was estimated using Duncan's multiple range test ( $p < 0.05$ ) (DUNCAN, 1955).

## RESULTS

As shown in Table 2, total bilirubin, ALP, GGT, AST, ALT, LDH and AFP significantly increased in paracetamol treated rats (group 3) by 41%, 34.8%, 63.3%, 55.5%, 80.4%, 140.4% and 224.3% respectively compared to the control group. The levels of those parameters decreased statistically in olive leaves extract plus paracetamol group (group4) by 25%, 42.3%, 32.4%, 15%, 16%, 42.5% and 33.8% respectively compared to the paracetamol treated rats (group3).

The results reported in Table 3 show that rats treated with paracetamol (group 3) had a significant increase in urea, creatinine and MDA, levels by 37.8%, 25% and 31.5%, respectively compared to the control. However the TAC, SOD and GR dropped by 43.3%, 38.8% and 51.28% respectively compared to the control. In rats administered olive leaves extract and paracetamol group (group 4), the values of urea, creatinine, MDA, were significantly decreased by 20.7%, 21% and 18.7% respectively with a significant increase in the levels of TAC, SOD and GR by 26.9%, 28.7, 89.41 respectively compared to the paracetamol treated rats (group3).

**Table 2.** Effects of olive leaves extract on liver function tests in paracetamol-induced hepatotoxicity in male albino rats

Groups Parameters	C	OLE	PCM	PCM+OLE
T.B(mg/dl)	0.78±0.05	0.69±0.10	1.10±0.09 <sup>ab</sup>	0.82±0.04 <sup>bc</sup>
% of change		-11.53fromC	4.02fromC	-25.45 from PC
ALP(u/l)	460.20±9.80	393.90±8.00 <sup>a</sup>	620.60±11.60 <sup>ab</sup>	357.60±7.60 <sup>c</sup>
% of change		-14.4 from C	34.8 from C	-42.3 from PCM
GGT(u/l)	49.40±3.50	49.50±2.80	80.70±3.10 <sup>ab</sup>	54.50±1.40 <sup>ac</sup>
% of change		0.2 from C	63.3from C	-32.4 from PCM
AST(u/l)	251.00±2.90	229.60±1.70 <sup>a</sup>	390.50±19.40 <sup>ab</sup>	331.00±13.70 <sup>abc</sup>
% of change		-8.5fromC	55.5fromC	-15from PCM
ALT(u/l)	135.00±1.80	106.30±2.60 <sup>a</sup>	243.50±14.20 <sup>ab</sup>	203.40±3.40 <sup>abc</sup>
% of change		-21.2 from C	80.4fromC	-16.4 from PCM
LDH(u/l)	306.70±5.40	267.20±28.00 <sup>a</sup>	737.40±19.20 <sup>b</sup>	423.80±37.10 <sup>bc</sup>
% of change		-12.8fromC	140.4fromC	-42.5 from PCM
AFP(ng/ml)	0.41±0.01	0.48±0.03	1.33±0.10 <sup>b</sup>	0.88±0.10 <sup>bc</sup>
% of change		17fromC	224.3fromC	-33.8 from PCM

The results are presented as means ± SEM of 6 rats, P-values of less than 0.05 were considered significant; C (control), OLE (olive leaves extract), PCM (paracetamol), PCM+OLE (paracetamol+olive leaves extract)

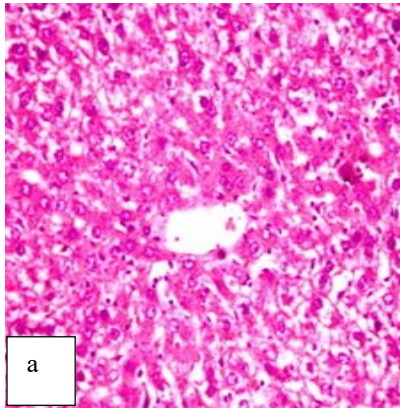
$$\% \text{ of change} = \frac{\text{treatment} - \text{control}}{\text{control}} \times 100$$

**Table 3.** Effect of olive leaves extract on kidney functions and oxidant and antioxidant status in paracetamol-induced hepatotoxicity in male albino rat

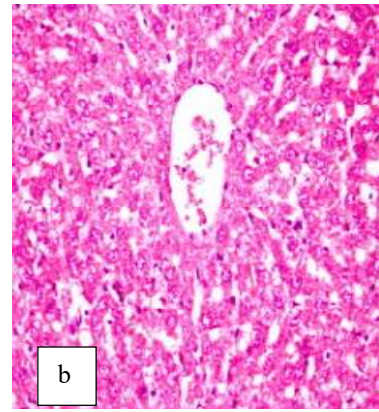
Group Parameters	C	OLE	PCM	PCM+OLE
Urea(mg/dl)	36.72±1.50	32.61±0.80 <sup>a</sup>	50.62±1.40 <sup>b</sup>	40.11±1.80 <sup>ac</sup>
% of change		-11.1fromC	37.8 fromC	-20.7 from PCM
Creatnine(mg/dl)	1.04±0.10	0.96±0.13	1.30±0.10 <sup>b</sup>	1.02±0.10 <sup>bc</sup>
% of change		-7.6fromC	25fromC	-21 from PCM
MDA(Mmol/g)	133.42±5.00	132.60±3.90	175.47±2.50 <sup>b</sup>	142.60±6.40 <sup>bc</sup>
% of change		-0.6fromC	31.5fromC	-18.7from PCM
TAC(ng/ml)	6.87±0.30	6.38±0.10	3.89±0.10 <sup>b</sup>	4.94±0.12 <sup>bc</sup>
% of change		-7.1fromC	-43.3fromC	26.9 from PCM
SOD(u/l)	39.70±5.20	41.49±1.30	24.32±0.90 <sup>b</sup>	31.31±1.10 <sup>bc</sup>
% of change		4.3fromC	-38.8fromC	28.7 from PCM
GR(ng/g)	3.49±0.04	2.45±0.04 <sup>a</sup>	1.70±0.02 <sup>b</sup>	3.22±0.02 <sup>ac</sup>
of change%		-29.7% from C	-51.28% from C	89.41% from PCM

The results are presented as means ± SEM of 6 rats, P-values of less than 0.05 were considered significant; C (control), OLE (olive leaves extract), PCM (paracetamol), PCM+OLE (paracetamol + olive leaves extract)

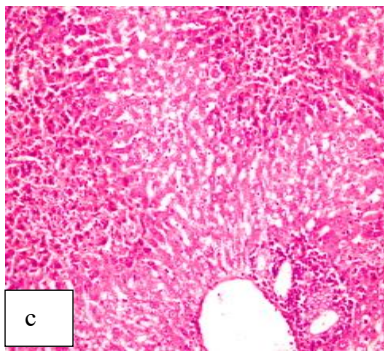
$$\% \text{ of change} = \frac{\text{treatment} - \text{control}}{\text{control}} \times 100$$



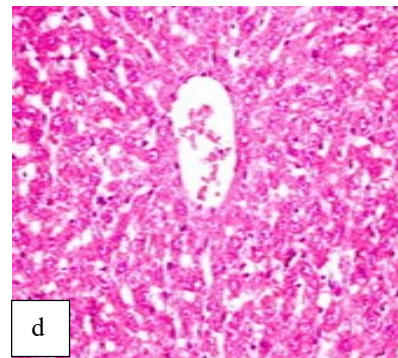
(1a): control group Liver showing apparently normal hepatocytes (H&E X 400)



(1b): olives leaves extract group Liver showing healthy hepatic cords and blood ((H&E 400)



(1c): paracetamol group Liver showing multiple focal areas of necrotic hepatocytes infiltrated with mononuclear cells (H&E X 400)



(1d): (paracetamol+ olive leaves extract group) Liver showing apparently normal hepatocyte (H&E X 400)

**Figure 1.** Liver histology

## DISCUSSION

The present study was conducted to evaluate the hepatoprotective activity of olive leaves extract against overdose of paracetamol. The results demonstrated that paracetamol- treated rats showed impairment in liver functions, which is confirmed by the enhancement of the levels of hepatic marker enzymes. There were significant increases in the levels of liver markers (AST, ALT, ALP, GGT) and LDH activities. These elevations are the major diagnostic signs of liver dysfunction. Consistent with the obtained results, other studies showed a change in hepatic serum markers following administration of paracetamol (AJAYI; ADENIYI; BABAYEMI, 2009; SHABANA et al., 2012), where the elevations in serum are presumptive markers of drug induced alteration in the hepatocytes. Similarly, recent results showed an elevation in the activities of hepatic marker enzymes in rats following administration of paracetamol

(ADEBIYI; ABATAN, 2013; PARMAR et al., 2013, ALANTARY; REZK; SOLIMAN, 2014; KUMAR; RAMESH; MOHAN, 2014; OZUGUIV; EYO, 2014; FOGHA et al., 2015; AJIBOYE, 2016; DWIVEDI et al 2016). Elevation in AST and ALT indicate a cellular damage and loss of functional integrity of the hepatocytes, and this elevation is attributed to leakage of plasma membrane of hepatocytes causing an increased serum hepatic enzymes. Gamma-glutamyltransferase (GGT), and alkaline phosphatase (ALP) are membrane bound enzymes. The elevation of GGT activity is regarded as one of the most sensitive indices of hepatic damage. Administration of olive leaves shows apparently normal hepatocytes. This effect is in agreement with the accepted view that serum levels of transaminases return to normal with the healing of hepatic parenchyma and the regeneration of hepatocytes (AHMED; KHATER, 2001; EL FARAS; ELSAWAF, 2017). LDH catalyses the

conversion of lactate to pyruvate using NAD<sup>+</sup> as coenzyme of NAD (BURTIS; ASHWOOD, 1986). The increase in LDH activity may be due to leakage of the enzyme from the tissues into the blood because of a cellular damage. The increase in ALP and bilirubin levels in paracetamol treated animals reflects the pathological alteration in biliary flow (ISLAM; ALAM, 2019). Hyperbilirubinemia was due to excessive heme destruction and block of bile duct within the liver, inhibition of the conjugation reaction and release of unconjugated bilirubin from damaged hepatocytes (HANAFY et al., 2016).

Treatment with olive leaves extract significantly improved the activities of hepatic markers. Consistent with the current data, previous studies revealed the hepatoprotective activity of aqueous extract of olive leaves against paracetamol overdose-induced destruction of liver cells in male albino rats (KHALIL, 2004; AL ATTAR; ABU ZAID, 2013). A significant decrease in the activities of hepatic enzymes in OLE treated rats confirmed the protective effect of the extract having various phytoconstituents such as fatty acid (oleonic and Pentaadecanoic acid, Octadecenoic acid, Cis-Vaccenic acid, and Stearic acid) and Flavonoides e.g., Isovitexin, Astibin, Quercetin, B-Sitosterol, which exhibit hepatoprotective properties and have a role in preserving structural integrity of the hepatocellular membrane that could be responsible for the membrane stabilizing activity.

Nephrotoxicity results when there is insufficient glutathione in the renal parenchyma and occurs independently of hepatotoxicity depending on the balance of metabolism and the glutathione stores within the kidney (BOUTIS; SHANNON, 2001). In the present study, paracetamol administration caused a significant increase in serum urea and creatinine levels, leading to renal damage. Elevation in plasma concentration of these parameters is considered reliable for investigating drug-induced nephrotoxicity in animals (MANDAL et al., 2015). These results were in accordance with previous studies (ANTHONY; MBUH; EMMANUEL, 2012; SAXENA et al. 2012; SINI; NWODO; ALUMANA, 2017) which reported that there was a significant increase in kidney markers (urea and creatinine) following administration of paracetamol overdose. Treatment with olive leaves extract resulted in decline of urea and creatinine in serum. This finding is in accordance with that of Zari and Al-Attar (2011) who reported that olive leaves extract ameliorated renal toxicity induced by carbendazim in rats. Additionally, Al-Sowayan and Mousa (2014) investigated the protective effect of olive leaves extract against CCl<sub>4</sub> induced

nephrotoxicity and reported that treatment with olive leaves extract significantly decline the elevation in urea and creatinine suggesting that the olive leaves extract protected CCl<sub>4</sub>-induced nephrotoxicity.

AFP is used as a diagnostic and predictive marker. In the present study, the results showed an increase in  $\alpha$ -feto protein in paracetamol treated group compared to the control. An increase in alpha-fetoprotein (AFP) following hepatic necrosis is considered indicative of hepatic regeneration. This result is in agreement with Schmidt and Dalhoff, (2005), who proved the occurrence of premalignant liver changes in intoxicated rats. Treatment with olive leaves extract significantly reduced serum AFP that may indicate the curative effect of OLE which was attributed to its polyphenol and flavonoids. This result is in accordance with Abdel-Hamid et al. (2011) who reported that administration of olive leaves extract significantly decreased the elevation in alpha feto protein (AFP) in hepatotoxicity rats induced by Trichloroacetic acid (TCA). The present finding was confirmed by histopathological alteration of liver in rats treated with paracetamol showing multiple focal area of necrotic hepatocytes infiltrated with mononuclear cells. The elevated level of MDA is in accordance with previous study of Farghaly and Hussein (2010), which showed the association between PCM toxicity and MDA. A significant elevation in hepatic MDA level weakling glutathione reductase (GR) activity, SOD and TAC was demonstrated in other studies (MANIMARAN; SARKAR; SANKAR, 2010; ALANTARY; REZK; SOLIMAN, 2014; WOJANAROVA et al., 2015; SAHEED, HENDRIK; TOM, 2016; AJIBOYE, 2016; AMIN et al., 2017). These studies suggested enhanced lipid peroxidation leading to tissue damage and failure of antioxidant defense. Administration of OLE significantly ameliorated these changes suggesting that OLE extract containing phyto constituents such as oleuropein and hydroxytyrosol reverses the chronic inflammation and oxidative stress. This is in accordance with some studies (TRIPOLI et al., 2005; BULOTTA et al., 2013). It was reported that olive leaves extract had a high radical scavenging activity (WOJCIKOWSKI et al., 2007).

## CONCLUSION

The finding of this study indicates that OLE possesses hepatoprotective properties against paracetamol overdose by inhibiting the physiological and histological alterations as well as decreasing oxidative stress.

**RESUMO:** A sobredosagem de paracetamol (PCM) pode causar hepatotoxicidade com estresse oxidativo; o presente estudo foi realizado para estabelecer o possível efeito protetor do extrato de folhas de oliveira (OLE) na toxicidade induzida pelo paracetamol em ratos machos adultos. Vinte e quatro ratos machos adultos foram divididos em quatro grupos iguais: controle, grupo extrato de folhas de oliveira, grupo paracetamol e extrato de folhas de oliveira mais grupo paracetamol. Alguns parâmetros bioquímicos e histopatologia hepática foram avaliados. O tratamento com PCM aumentou significativamente aspartato aminotransferase sérica (AST), alanina aminotransferase (ALT), bilirrubina total, gama-glutamyltransferase (GGT), lactato desidrogenase (LDH), uréia, creatinina e alfa-fetoproteína. Verificou-se que o paracetamol aumenta significativamente o malonaldeído (MDA) e diminui a atividade da glutathione redutase (GR) no tecido e diminui significativamente a capacidade antioxidante total (TAC) e a superóxido dismutase (SOD) no soro. A administração de OLE causou uma diminuição significativa de AST, enzima ALT, bilirrubina total, GGT, LDH, creatinina, uréia, alfa-fetoproteína. Também foi observada melhora do status oxidante - antioxidante com extrato de folhas de oliveira, além de uma diminuição significativa no MDA e um aumento significativo no TAC no tecido hepático, com um aumento significativo na glutathione redutase (GR) e SOD no soro em comparação ao grupo tratado com paracetamol. As alterações patológicas químicas acompanharam a observação histopatológica, sugerindo resultado hepatoprotetor acentuado do extrato de folhas de oliveira. Pode-se concluir que o tratamento com extrato de folhas de oliveira (OLE) pode ser eficaz na diminuição da lesão hepática e do estresse oxidativo induzido pela overdose de paracetamol em ratos albinos machos

**PALAVRAS-CHAVE:** Paracetamol. Extrato de folhas de oliveira. Enzimas hepáticas. Estado oxidante-antioxidante.

## REFERENCES

- ABDEL-HAMID, N. M.; FAWZY, M. A.; EL-MOSELHY, M. A. Evaluation of Hepatoprotective and Anticancer Properties of Aqueous Olive Leaf Extract in Chemically Induced Hepatocellular Carcinoma in Rats. **American Journal of Medicine and Medical Sciences**, V.1, n.1, p. 15-22, 2011. [http:// DOI: 10.5923/j.ajmms.20110101.03](http://doi.org/10.5923/j.ajmms.20110101.03)
- ADEBIYI, E. O.; ABATAN, O. M. Protective Effects of Enantia chlorantha Stem Bark Extracts on Acetaminophen Induced Liver Damage in Rats. **J.J.B.S**, v. 6, n 4, p. 284-290, 2013. <https://www.researchgate.net/publication/270879318> <https://doi.org/10.12816/0001627>
- AHMED, M. B.; KHATER, M. R. Evaluation of the protective potential of *Ambrosia maritime* extract on acetaminophen induced liver damage. **J Ethnopharmacol** , v. 75, n. 2-3, p.169–174,2001 [https://doi.org/10.1016/S0378-8741\(00\)00400-1](https://doi.org/10.1016/S0378-8741(00)00400-1)
- AJAYI, G. O.; ADENIYI, T. T.; BABAYEMI, D. O. Hepatoprotective and some haematological effects of Allium sativum and vitamin C in lead exposed wistar rats. **Inter .J .Medicine and Medical. Sci.**, v .1,n. 3, p .064-067,2009 .<http://www.academicjournals.org/ijmms>
- AJIBOYE, O. T. Lophirones B and C Attenuate Acetaminophen-Induced Liver Damage in Mice: Studies on Hepatic, Oxidative Stress and Inflammatory Biomarkers. **Journal of Biochemical and Molecular Toxicology**, v.10, n.5, p.497-505, 2016. <https://doi.org/10.1002/jbt.21814>.
- AL ATTAR, M. A.; ABU ZAID, M. I. Effect of Tea (*Camellia sinensis*) and Olive (*Olea europaea* L.) Leaves Extracts on Male Mice Exposed to Diazinon. **Bio Med Research International** ,v. 2013, p.1-6, 2013. <http://dx.doi.org/10.1155/2013/461415>
- ALANTARY, A. K.; REZK, M. Y.; SOLIMAN, K. E. A. Protective effect of ghrelin on paracetamol induced acute hepatotoxicity in rats. **Journal of physiology and pathophysiology**, v.5,n.2,p.7-14,2014. <https://doi.org/10.5897/JPAP2014.0091>



Possible protective...

TAHA, M. E. S.; KAMAL, A. M.; IBRAHIM, D. R.

AL-BASHER, G. I. Anti -fibrogenic and hepatoprotective potential of methanolic olive extract on cadmium induced toxicity in rats. **Life Science Journal**, v.15,n.7,p.1-11,2018. <http://www.lifesciencesite.com>. doi:10.7537/marslsj150718.01

AL-SOWAYAN, N. S.; MOUSA, H. M. Ameliorative effect of olive leaf extract on carbon tetrachloride-induced nephrotoxicity in rats, **Life. Science Journal**. v11.n5.p238-242,2014. <https://www.researchgate.net/publication/262297713>

AMIN, K. A.; HASHEM, K. S.; ALSHEHRI, F. S.; AWAD, S. T.; HASSAN, M. S. Antioxidant and Hepatoprotective Efficiency of Selenium Nanoparticles Against Acetaminophen-Induced Hepatic Damage. **Biol. Trace Elem. Res**, v. 175, n.1, p. 136-145,2017. <https://www.ncbi.nlm.nih.gov/pubmed/27220627> <https://doi.org/10.1007/s12011-016-0748-6>

ANTHONY, O. E; MBUH ,A. F.; EMMANUEL, M. P. Phytochemical screening, and assessment of ameliorating effect of aqueous and ethanolic extracts of Gmelina arborea on drug induced hepatic and renal insufficiency in rats. **Pak J Pharm Sci**, v. 25, n. 2, p. 457–461,2012. <https://www.ncbi.nlm.nih.gov/pubmed/22459477>

BANCROFT, D.; STEVEN, A.; TURNER, R.. Theory and practice histological techniques. 4th ed Churchill livingstone, Edinburgh, London, Melbourne. v. 183, n. 2, p. 127-248,1996. <https://onlinelibrary.wiley.com>

BULOTTA, S.; OLIVERIO, M.; RUSSO, D.; PROCOPIO, A. Biological activity of oleuropein and its derivatives. In: Ramawat K. G., Mérillon J. M., editors. **Natural Products. Heidelberg, Germany: Springer**, p. 3605–3638, 2013. <https://www.ncbi.nlm.nih.gov/pmc/articles/PMC4700197/> [https://doi.org/10.1007/978-3-642-22144-6\\_156](https://doi.org/10.1007/978-3-642-22144-6_156)

BOUTIS, K.; SHANNON, M. Nephrotoxicity After acute severe acetaminophen poisoning in adolescents. **J. Toxicol. Clin.Toxicol**, v. 39, n.5, p.441-5, 2001. <https://www.ncbi.nlm.nih.gov/pubmed/11545233> <https://doi.org/10.1081/CLT-100105413>

BURTIS, L. A.; ASHWOOD, E. R. Textbook for Clinical Chemistry. W.B. Saunders Company, Philadelphia, Pennsylvania, 1986.

CHINNAPPAN, S. M.; GEORGE, A.; THAGGIKUPPE, P.; CHOUDHARY, Y.; CHOUDHARY, V. K.; RAMANI, Y.; DEWANGAN ,R. Nephroprotective Effect of Herbal Extract Eurycoma longifolia on Paracetamol-Induced Nephrotoxicity in Rats , **Evidence-Based Complementary and Alternative Medicine** V. 2019, 2019, Article ID 4916519, 6 pages <https://doi.org/10.1155/2019/4916519>

DAS, J.; GHOSH, J.; MANNA, P.; SIL, P. C. A. Acetaminophen induced acute liver failure via oxidative stress and JNK activation: protective role of taurine by the suppression of cytochrome P450 2E1. **Free. Radical. Research** ,v. 44, n. 3, p. 340-55,2010. <https://doi.org/10.3109/10715760903513017>

DAVID, H.; RICHARD, J. S; In: Bergmeyer J, Grab M. editors. Methods of enzymatic analysis. rd ed., Verlag Chemie; Weinheim Deer Field Beach, P. 358, 1983.

DUNCAN, D.B. Multiple F test. **Biometrics**, p. 1-142, 1955.

DWIVEDI, K. V.; MISHRA, J; SHRIVASTAVA, A. Efficacy study of Livartha against paracetamol induced Hepatotoxicity in adult Sprague Dawley Rats. **Drug Metabolism and Toxicology**, v.5,n.6,p.1-7,2016. <https://doi.org/10.4172/2157-7609.1000175>

EL FARAS, A. A; ELSAWAF, A. L. Hepatoprotective activity of quercetin against paracetamol-induced liver toxicity in rats. **Tanta Med J** , v.45, n.2, p.92-8,2017. <http://www.tdj.eg.net/text.asp?2017/45/2/92/216690> [https://doi.org/10.4103/tmj.tmj\\_43\\_16](https://doi.org/10.4103/tmj.tmj_43_16)



Possible protective...

TAHA, M. E. S.; KAMAL, A. M.; IBRAHIM, D. R.

FARGHALY, H. S.; HUSSEIN, M. A. Protective effect of curcumin against paracetamol-induced liver damage. **Australian Journal of Basic and Applied Sciences** V. 4, n. 9, p. 4266-4274, 2010.

<https://www.researchgate.net/publication/279718136>

FOGHA, J. V.; TCHAMGOUE, D. A.; DOMEKOUO, L. U.; TAKANG, P. A.; AGBOR, G. A. Morinda Lucida Stem Bark Protects Paracetamol induced liver damage. **Int. J. Pharm. Sci. Rev. Res.**, v.31, n.1 p.198-204, 2015.

<https://www.researchgate.net/publication/273502248>

HAKEMI, S. G.; SHARIFIFAR, F.; HAGHPANAH, T.; BABAEE, A.; EFTEKHAR-VAGHEFI, S.H. The Effects of Olive Leaf Extract on The Testis, Sperm Quality and Testicular Germ Cell Apoptosis in Male Rats Exposed to Busulfan. **Int J Fertil Steril**, v. 13, n.1, p. 57-65, 2019.

<https://www.ncbi.nlm.nih.gov/pmc/articles/PMC6334023>

HANAFY, A.; ALDAWSARI, M. H.; BADER, M. J.; IBRAHIM, A. K.; ABDELHADY, S. E. Evaluation of Hepatoprotective Activity of Adansoniadigitata Extract on Acetaminophen-Induced Hepatotoxicity in Rats.

**Evidence-Based Complementary and Alternative Medicine**, v. 2016, P. 1-7 2016.

<http://dx.doi.org/10.1155/2016/4579149>

ISLAM, R.; ALAM, M. J. Evaluation of liver protective activity of *Moringa oleifera* bar` extract in paracetamol induced hepatotoxicity in rats. **bioRxiv**, Jan, p.513002, 2019. <http://dx.doi.org/10.1101/513002>

KAKKAR, P.; DAS, B.; VISWANATHAN, P. N. A modified spectrophotometric assay of superoxide dismutase. **Indian J. Biochem. Biophys.**, v.21, p. 130-162, 1984.

<https://pdfs.semanticscholar.org/ed30/b1024e83d2b22089f0419ca5fb73a3e0faa5.pdf>

KHALIL, E. A. M. Evaluation of the hepatoprotective activity of an aqueous extract of olive leaves in male albino rats. **Egypt. J. Hosp. Med.**, v. 15, p.118-123, 2004. DOI: 10.12816/EJHM.2004.18191

KIM, M. S. J.; LEE, M. Y.; KWON, D. Y.; KIM, S. Y.; KIM, Y. C. Alteration in metabolism and toxicity of acetaminophen upon repeated administration in rats, **J. Pharmacol. Sci.**, v.111, n.2, p. 175-81, 2009.

<https://www.ncbi.nlm.nih.gov/pubmed/19834287> <https://doi.org/10.1254/jphs.09151FP>

KROES, R. S.; SONTAG, J. M.; SELL, S.; WILLIAMS, G. M.; JOHN, H.; WEISBURGER, J. H. Elevated Concentration of Serum a Fetoprotein in Rats with Chemically Induced Liver Tumors. **Cancer Research**, v.35, p.1214-1217, 1975. <https://www.ncbi.nlm.nih.gov/pubmed/47266>

KUMAR, C. H.; RAMESH, A.; MOHAN, G. K. Hepatoprotective Effect Of Ethanollic Extract Of *Ficus Mollis* On Paracetamol Induced Liver Damage In Albino Rats. **International Research Journal Of Pharmacy**, v.5, n. 6, p.485-488, 2014. <https://www.researchgate.net/publication/271236428> <https://doi.org/10.7897/2230-8407.0506100>

MANDAL, A.; PATRA, A.; MANDAL, S.; ROY, S.; MAHAPATRA, S. D.; MAHAPATRA, T. D.; PAUL, T.; DAS, K.; MONDAL, K. C.; NANDI, D. K. Therapeutic potential of different commercially available synbiotic on acetaminophen-induced uremic rats. **Clin. Exp. Nephrol.**, v.19, n.2, p. 168-177, 2015.

<https://link.springer.com/article/10.1007/s10157-014-0971-4>

MANIMARAN, A.; SARKAR, S. N.; SANKAR, P. Influence of repeated preexposure to arsenic on acetaminophen-induced oxidative stress in liver of male rats, **Food and Chem. Toxicol**, v. 48, n.2, p.605-610, 2010. <https://www.ncbi.nlm.nih.gov/pubmed/19932728> <https://doi.org/10.1016/j.fct.2009.11.039>

MCGILL, M. R.; WILLIAMS, C. D.; XIE, Y.; RAMACHANDRAN, A.; JAESCHKE, H. Acetaminophen-induced liver injury in rats and mice: comparison of protein adducts, mitochondrial dysfunction, and oxidative stress in the mechanism of toxicity. **Toxicol. Appl. Pharmacol.**, v.1 n. 264(3) p. 387-94, 2012 doi:

10.1016/j.taap.2012.08.015. Epub 2012 Aug 23 PMID: 22980195 <https://doi.org/10.1016/j.taap.2012.08.015>

Possible protective...

TAHA, M. E. S.; KAMAL, A. M.; IBRAHIM, D. R.

MOHAMED-SALEEM, T.; CHETTY, S.; M.; RANKANTH, S.; RAJAN, V.; S.; T.; KUMAR, K.; M.; GANTHAMAN, K. Hepatoprotective Herbs a review. **Inter. J. Res .Pharmaceutical. Sci**, v. 1, n. 1, p.1-5, 2010. <https://www.pharmascope.org>

OHKAWA, H.; OHISHI, N.; YAGI, K. Assay for lipid peroxides in animal tissues by thiobarbituric acid reaction, **Anal. Biochem**, v. 95, n. 2, p.351-358, 1979. <https://www.ncbi.nlm.nih.gov/pubmed/36810>  
[https://doi.org/10.1016/0003-2697\(79\)90738-3](https://doi.org/10.1016/0003-2697(79)90738-3)

OZOUGWU, J. C. and EYO, J. E. Hepatoprotective effects of Allium Cepa (onion) extracts against paracetamol induced liver damage in rats. **African. Journal of Biotechnology**, v. 13 n. 26, p.2679-2688, 2014. <https://doi.org/10.5897/AJB2014.13815>

PARMAR, M. Y.; SHAH, P. A.; VAISHALI, T.; THAKKAR, V. T.; AL-REJAIE, S.; ABDULLAH, H.; AL-ASSAF, A. H.; GANDHI, T. R. Hepatoprotective and antioxidant activity of methanolic extract of vetiveria zizanioides roots against paracetamol-induced liver damage in rats **Life Science Journal**, v.10, n. 4, p.1184-1190, 2013. <https://www.researchgate.net/publication/258240460>

RUSSMANN, S.; KULLAK-UBLICK, G.A.; GRATAGLINO, I. Current concepts of mechanism in drug induced hepatotoxicity, **Curr. Med. Chem**, v. 16, n. 23, p. 3041-3053, 2009. <https://www.ncbi.nlm.nih.gov/pubmed/19689281> <https://doi.org/10.2174/092986709788803097>

SAHEED, S.; HENDRIK, F. O.; TOM, A. A. Zea mays, Stigma maydis prevents and extenuates acetaminophen-perturbed oxidative onslaughts in rat hepatocytes, **Pharmaceutical. Biology**, v. 9, n. 5, p.2664-2673, 2016. <https://www.ncbi.nlm.nih.gov/pubmed/27159805> <https://doi.org/10.1080/13880209.2016.1178307>

ŞAHIN, S.; ŞAMLI, R. Optimization of olive leaf extract obtained by ultrasound-assisted extraction with response surface methodology, **Ultrason. Sonochem**, v. 20, n. 1, p.595–602, 2013. <https://www.ncbi.nlm.nih.gov/pubmed/22964032> <https://doi.org/10.1016/j.ultsonch.2012.07.029>

SARBISHGI, M.; GORGICH, E. A. C.; KHAJAVI, O. Olive Leaves Extract Improved Sperm Quality and Antioxidant Status in the Testis of Rat Exposed to Rotenone. **Nephro .urol .Mon**, v. 9, n. 3, p. e47127, 2017. <https://www.researchgate.net/publication/316490653> <https://doi.org/10.5812/numonthly.47127>

SAXENA, M.; SHAKYA, A.; K.; SHARMA, N.; SHRIVASTAVA, S.; SHUKLA, S. Therapeutic efficacy of Rosa damascena Mill. On acetaminophen-induced oxidative stress in albino rats. **J Environ Pathol Toxicol Oncol**, v.31, n.3, p.193–201, 2012 <https://www.ncbi.nlm.nih.gov/pubmed/23339694>  
<https://doi.org/10.1615/JEnvironPatholToxicolOncol.v31.i3.10>

SCHMIDT, L.; E.; DALHOFF, K. Alpha-fetoprotein is a predictor of outcome in acetaminophen-induced liver injury, **Hepatology**, v. 41, n. 1, pp. 26–31, 2005. <https://www.ncbi.nlm.nih.gov/pubmed/15690478>  
<https://doi.org/10.1002/hep.20511>

SEHRAWAT, A.; KHAN, T. H.; PRASAD, L.; SULTANA, S. Buteamonosperma and chemomodulation : protective role against thioacetamide mediated hepatic alterations in Wister rats, **Phytomed**, v.13, n. 3, p. 157-163, 2006. <https://www.ncbi.nlm.nih.gov/pubmed/16428022> <https://doi.org/10.1016/j.phymed.2004.11.007>

SHABANA, M.; B.; IBRAHIM, H.; M.; SOHEIR, E. M.; MARWA, G. E. Influence of rifampicin and tetracycline administration on some biochemical and histological parameters in albino rats. **The journal of Basic & Applied Zoology**, v. 65, n.5, p. 299-308, 2012. <https://www.researchgate.net/publication/257737069>  
<https://doi.org/10.1016/j.jobaz.2012.10.009>

SINI, J.; M.; NWODO, O.; F.; C. ALUMANAH, E.; O. Hepatoprotective activity of aqueous extract of Combretum sericeum roots against paracetamol induced hepatic damage in rats, **Journal of Scientific Research and Studies**, v.4, n. 2, p. 40-46, 2017. <http://www.modernrespub.org/jsrs/index.htm>

Possible protective...

TAHA, M. E. S.; KAMAL, A. M.; IBRAHIM, D. R.

SUBRAMONIAM, A.; EVANS, D. A.; RAJASKAHRAN, S. P.; PUSHPANGADAN, P. Hepatoprotective activity of *Trichopus Zeylanicus* extracts against paracetamol induced damage in rats, **Ind. J .Expect. Biol**, v. 36, n.4, p.385-389, 1988 . <https://www.ncbi.nlm.nih.gov/pubmed/9717449>

TRIPOLI, E.; GIAMMANCO, M.; TABACCHI, G.; MAJO, D.; GIAMMANCO, S.; GUARDIA, M. The phenolic compounds of olive oil: structure, biological activity and beneficial effects on human health, **Nutr. Res. Rev.**, v. 18, n. 1, p.98–112, 2005. <https://www.ncbi.nlm.nih.gov/pubmed/19079898>  
<https://doi.org/10.1079/NRR200495>

WANG, L.; GENG, C.; JIANG, L.; GONG, D.; LIU ,D.; YOSHIMURA, H.; ZHONG, L. The anti-atherosclerotic effect of leaves extract is related to suppressed inflammatory response in rabbits with experimental atherosclerosis, **Eur. J .Nutr**, v.47, n. 5, p.235-43, 2008.  
<https://www.ncbi.nlm.nih.gov/pubmed/18654736> <https://doi.org/10.1007/s00394-008-0717-8>

WOJANAROVU, L.; KUTINOVA CANOVA, N.; FARGHALI, H.; KUCERA, T. Sirtuin 1 Modulation in Rat Model of Acetaminophen-Induced hepatotoxicity **Physiol Res**, v.64, n. 4, p. S477-87,2015.  
<https://www.ncbi.nlm.nih.gov/pubmed/26681077>

WOJCIKOWSKI, K. L. STEVENSON, D. LEACH, H. WOHLMUTH; G. GOBE,,: Antioxidant capacity of 55 medicinal herbs traditionally used to treat the urinary system: a comparison using a sequential three-solvent extraction process. **The Journal of Alternative and Complementary Medicine**, v.13, n.1, p.103-110, 2007 .<https://doi.org/10.1089/acm.2006.6122>

ZARI, T.A; AL-ATTAR, A. ; M. Therapeutic effects of olive leaves extract on rats treated with a sublethal concentration of Carbendazim, **Eur. Rev. Med. Pharmacol. Sci**, v.15, n. 4, 413-426, 2011.  
<https://www.ncbi.nlm.nih.gov/pubmed/21608437>