

# FUNGAL ENDOCARDITIS DUE TO *TRICHOSPORON ASAHII*: A RARE CASE REPORT IN IMMUNOCOMPETENT SUBJECT

## ENDOCARDITE FÚNGICA POR *TRICHOSPORON ASAHII*: RELATO DE UM CASO RARO EM IMUNOCOMPETENTES

Rafael Petracca Pistori<sup>1</sup>,  
Victor Moreschi Neto<sup>1</sup>,  
Sarah Fagundes Grobe<sup>1</sup>,  
Luka David Lechinewski<sup>1</sup>,  
Francisco Maia da Silva<sup>1</sup>

1. Irmandade Santa Casa de  
Misericórdia de Curitiba, PR, Brazil.

Correspondence:  
Rafael Petracca Pistori,  
Praça Rui Barbosa, 694, Centro,  
Curitiba. CEP 80010-030, Irmandade  
Santa Casa de Misericórdia de  
Curitiba-PR, Brazil.  
rafaelpetracca@yahoo.com.br

Received on 10/26/2017,  
Accepted on 10/05/2018

### ABSTRACT

**Objective:** To present the case report of an immunocompetent patient with multiple aortic valve replacements, diagnosed with fungal endocarditis due to *T. asahii*. **Case report:** A 63-year-old male patient with a history of rheumatic fever and four aortic valve replacements, who progressed with symptoms of acute heart failure and fever. No evidence of immunosuppression was found. Laboratory tests detected mild anemia and thrombocytopenia, with normal leukogram and elevated lactate dehydrogenase and C-reactive protein levels. The echocardiogram revealed severe aortic insufficiency and multiple aortic valve vegetations. *T. asahii* was isolated in two blood cultures, and administration of amphotericin B was initiated. The patient required emergency surgery for a further valve replacement due to clinical deterioration. The patient later died as a result of intraoperative complications. **Discussion:** Diagnosis and treatment of *T. asahii* endocarditis are not well established in the literature. The currently available antifungals are triazoles and amphotericin B, with evidence suggesting superiority of the former, but surgery is required because of the ineffectiveness of these drugs alone. **Conclusions:** There is insufficient data on the safest and most effective pharmaceutical treatment for *T. asahii* endocarditis. In this case, the previous valve replacements added technical difficulty to the new procedure, which resulted in an unfavorable outcome. There is no data in the literature on the optimal timing for valve replacement in patients with multiple prior replacements.

**Keywords:** Endocarditis; Aortic Valve Insufficiency; Trichosporon.

### RESUMO

**Objetivo:** Relatar o caso de um paciente com múltiplas trocas valvares aórticas, imunocompetente, com diagnóstico de endocardite fúngica por *T. asahii*. **Relato do caso:** Homem, 63 anos, com história de febre reumática e quatro trocas da valva aórtica que evoluiu com sintomas de insuficiência cardíaca aguda e febre. Não foi encontrada nenhuma evidência de imunossupressão. Os exames laboratoriais demonstraram anemia e plaquetopenia leves, com leucograma normal e elevação de lactato desidrogenase e proteína C reativa. O ecocardiograma revelou insuficiência aórtica importante e múltiplas vegetações na valva aórtica. *T. asahii* foi isolado em duas hemoculturas, sendo iniciada a administração de anfotericina B. O paciente necessitou de cirurgia de emergência para nova troca valvar por deterioração clínica. Em decorrência de complicações intraoperatórias, evoluiu para óbito. **Discussão:** O diagnóstico e o tratamento da endocardite por *T. asahii* não estão bem estabelecidos na literatura. Os antifúngicos disponíveis atualmente são triazóis e anfotericina B, com evidências que sugerem superioridade dos triazóis, mas a cirurgia é necessária por ineficácia desses fármacos isoladamente. **Conclusões:** Faltam dados sobre o tratamento medicamentoso mais eficaz e seguro para a endocardite por *T. asahii*. Neste caso, as trocas valvares prévias agregaram dificuldade técnica ao novo procedimento, que resultou em evolução desfavorável. Não há dados de literatura sobre o momento ideal para troca valvar em pacientes com múltiplas trocas valvares prévias.

**Descritores:** Endocardite; Insuficiência da Valva Aórtica; Trichosporon

## INTRODUCTION

Fungal endocarditis, the most severe form of infective endocarditis, has a high mortality rate.<sup>1,2</sup> Its diagnosis and treatment remain very challenging, with an unfavorable prognosis in most cases due to late diagnosis. The most common causes of fungal endocarditis are the fungal species of the genera *Candida* and *Aspergillum*.<sup>3,4</sup>

*Trichosporon* species are yeasts broadly distributed in nature and isolated from the human pharynx and skin. Some studies reported a disseminated deep mycosis associated with *Trichosporon* species. The incidence of trichosporonosis in patients with deep mycoses is approximately 5%.<sup>5</sup> It is noteworthy that this type of fungus causes fatal opportunistic infections in immunocompromised hosts.<sup>6</sup> Among the many *Trichosporon* species, *T. cutaneum* and *T. beigellii*, are pathogenic. The name *T. beigellii*, widely used in the literature, is uncharacterized due to the lack of a satisfactory description or culture with accurate identification. Most cases of *Trichosporon* infection previously attributed to *T. beigellii* and *T. cutaneum* were probably caused by *T. asahii*.<sup>5</sup>

*T. asahii* is part of the normal human flora. However, it can cause superficial and deep infections. This fungus has been linked to life-threatening infections such as infective endocarditis, almost exclusively in immunocompromised patients.<sup>6</sup>

## OBJECTIVE

To report a case of an immunocompetent patient with a previous history of four aortic valve replacements who developed fungal endocarditis caused by *T. asahii*.

## CASE REPORT

A 63-year-old man with a 2-month history of fever up to 39°C developed dyspnea associated with orthopnea and nocturnal paroxysmal dyspnea 4 days before hospitalization. The patient had a history of rheumatic fever and four aortic valve replacements in 1997, 2005, 2014, and 2016, the last being replacement with a biological valve due to thrombosis of the previous metallic valve. A former smoker with a low smoking burden, the subject had quit smoking more than 30 years prior to admission. A physical examination showed a grade 3/6 systolic murmur in the aortic area with carotid radiation and hepatomegaly.

Laboratory tests at admission revealed anemia, hemoglobin 9.2 g/dL, globular volume 27.1%, leukocyte count 8,100/mm<sup>3</sup>, platelet count 35,000/mm<sup>3</sup>, C-reactive protein level 220 mg/L, lactate dehydrogenase 2,200 U/L, creatinine 1.2 mg/dL, and mildly elevated transaminases (approximately double the reference value). Echocardiography revealed a right bundle branch block. Transthoracic echocardiography showed an ejection fraction of 53% with increased mean aortic transvalvular gradient from 17 to 25 mmHg and maximum speed from 2.7 to 3.37 m/s compared to a previous examination. It also showed significant reflux (pressure half-time 177 ms) and the presence of vegetation on the ventricular face of the aortic valve measuring 17 × 11 mm. This last examination also showed an enlarged left atrium (60 mL/m<sup>2</sup>), severe tricuspid reflux, pulmonary artery systolic pressure 78 mmHg, systolic borderline function of an enlarged right ventricle, moderate eccentric hypertrophy of the left ventricle, and mild

basal anterior and mid-inferior hypokinesis. Transesophageal echocardiography showed no atrial appendage thrombus and revealed vegetations in the aortic valve measuring 0.8 × 0.8 mm in the right cusp, 0.7 × 0.7 mm and 0.8 × 0.5 mm in the left cusp, and 0.7 × 0.4 mm at the junction of the left and non-coronary cusps.

Once the diagnosis of subacute infective endocarditis was made, vancomycin was prescribed empirically. The two collected blood culture samples tested positive for *T. asahii* (Figures 1A, 1B). Thereafter, amphotericin B was prescribed. Computed tomography scans of the skull and abdomen were negative for abscesses and fungus balls. The patient's renal function worsened severely on the fourth day of vancomycin therapy and the second day of amphotericin B therapy, presenting a creatinine level of 2.9 mg/dL (creatinine clearance, 22 mL/min/1.73 m<sup>2</sup>) and treatment-refractory pulmonary congestion requiring intermittent hemodialysis. Despite the previous warning of the cardiac surgeon regarding the probable technical difficulty of the procedure due to the progressive worsening of the patient's clinical condition, an emergency aortic valve replacement was performed. (Figure 2)

The patient died intraoperatively due to surgical complications caused by friable myocardial tissue, which impeded the fixation of a new aortic valve prosthesis, and uncontrollable bleeding despite the transfusion of fresh plasma and packed red blood cells.

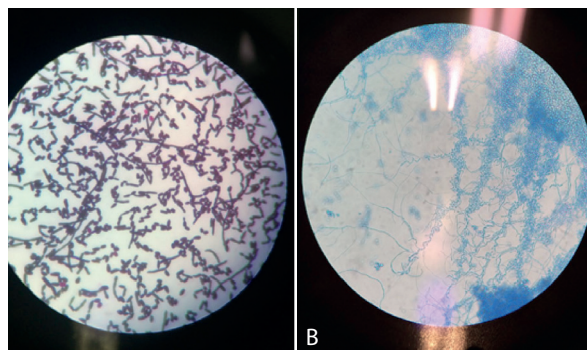


Figure 1. Diagnosis of *Trichosporon asahii* endocarditis.

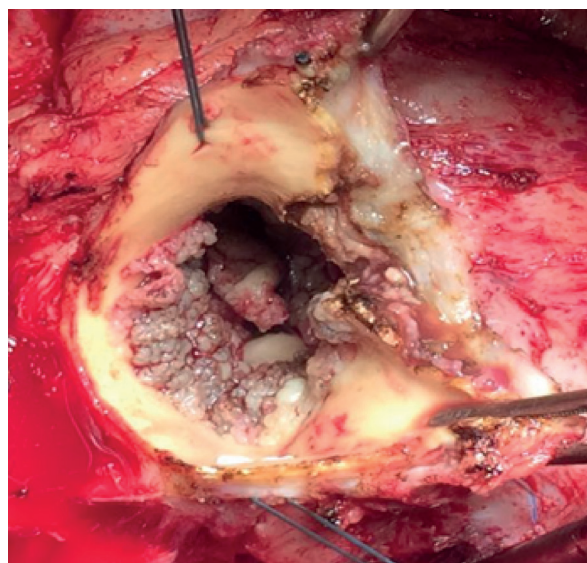


Figure 2. Aortic valve replacement surgery for the treatment of fungal endocarditis.

## DISCUSSION

Risk factors for *Trichosporon* spp. endocarditis include blood neoplasms and other states of immunosuppression; parenteral nutrition; the use of injectable drugs; newborn status; extensive burns; use of invasive devices such as a central venous access catheter, pacemaker, implantable cardioverter defibrillator, or prosthetic valves; and peritoneal dialysis therapy.<sup>4,8</sup>

The ability to form biofilms on implantable devices may contribute to the progression of invasive trichosporonosis as well as increase antifungal drug resistance and the host immune responses.<sup>9</sup> Di Bonaventura *et al.* tested the susceptibility profile of planktonic cells and *T. asahii* biofilms to amphotericin B, caspofungin, fluconazole, and voriconazole. *T. asahii* biofilms were resistant to all antifungal agents tested (minimum inhibitory concentration > 1.024 µg/mL) and up to 16,000 times more resistant to voriconazole than planktonic cells.<sup>9</sup> Fungi of the genus *Trichosporon* spp. can also produce proteases and lipases that further increase their virulence, such as the beta-*N*-acetylhexosaminidase produced by *T. asahii*.<sup>9</sup> Finally, *Trichosporon* spp. express glucuronoxylomannan, a polysaccharide that can reduce the *in vivo* phagocytic capacity of neutrophils and monocytes, in their cell walls.<sup>9</sup>

*T. asahii* infections should be diagnosed using cultures of fluids collected from the affected site. Blood cultures are usually positive in disseminated infections<sup>5,9</sup> but were negative in approximately 20% of confirmed cases of infective endocarditis.<sup>4</sup> In addition to positive blood cultures, cerebrospinal fluid cultures that test positive for *Trichosporon* spp. or biopsy specimens showing histopathological evidence of fungal elements compatible with *Trichosporon* spp. confirm the diagnosis of invasive trichosporonosis.<sup>5,9</sup> In cases in which it is impossible to collect biopsy or culture samples, β-D-glucan testing has been widely used for the early diagnosis of invasive fungal infections; however, few trichosporonosis studies report using this test.<sup>8,9</sup> The detection of glucuronoxylan antigen (also known as *Cryptococcus* capsular antigen) may also be useful for the early diagnosis of trichosporonosis despite limited clinical data on its usefulness for diagnosing invasive trichosporonosis.<sup>5,8,9</sup> More recently, polymerase chain reaction methods and flow cytometry assays have been tested for their ability to diagnose invasive *Trichosporon* spp. infections, although they have not yet been standardized for routine use.<sup>9</sup>

The optimal pharmacological treatment for trichosporonosis is still not well established.<sup>5,7</sup> Most studies showed that triazoles have the lowest inhibitory concentration values for these fungi, particularly voriconazole.<sup>9</sup> In a systematic review, voriconazole significantly improved the prognosis of patients with blood neoplasms and invasive trichosporonosis, corroborating the recent recommendations of the European Society of Clinical Microbiology and Infectious Diseases.<sup>8</sup> Some studies reported that triazoles (fluconazole and voriconazole) had better therapeutic effects than amphotericin B for invasive *T. asahii* infections.<sup>5,8,10</sup> *T. asahii* also seems more resistant to amphotericin B than other species of the genus.<sup>8,9</sup> Another study recommended combined triazole and amphotericin B therapy for *T. inkin* endocarditis.<sup>11</sup> Echinocandins have little or no activity against *Trichosporon* spp. and are not recommended to treat trichosporonosis.<sup>5,8,9</sup>

A meta-analysis of 879 cases of fungal endocarditis showed a trend toward mortality reduction with surgical treatment of the affected valve.<sup>4</sup> According to the 2015 European Guideline for the management of infective endocarditis, emergency valve replacement in patients with fungal endocarditis in native or prosthetic valves on the left side of the heart is a class I recommendation with a C evidence level.<sup>6</sup> Valve replacement should be associated with drug treatment since isolated antifungal therapy is usually ineffective.<sup>4,6,12</sup> Endocarditis caused by *Trichosporon* species in native or prosthetic valves is considered rare in immunocompetent patients despite the recent increase in reported cases. Patients usually develop large vegetations that can lead to embolic phenomena. Valvular replacement is mandatory, but infection recurrence is very common and the prognosis is usually guarded regardless of the antifungal therapy used.<sup>9</sup>

Lifelong treatment with azole derivatives postoperatively should be considered due to the high recurrence rate.<sup>4,6</sup> A case report on *T. asahii* endocarditis in the mitral and aortic valves described that a treatment using fluconazole and aortic and mitral valve replacement led to successful follow-up.<sup>5</sup>

*Trichosporon* spp. infection severity, late diagnosis, and the absence of a standardized antifungal treatment for trichosporonosis lead to a very high mortality rate of 44–83% and related poor prognosis.<sup>5,7,8</sup>

## CONCLUSIONS

*T. asahii* endocarditis is relatively rare; however, its incidence has increased in recent years. The disease is usually diagnosed using blood cultures, but making the diagnosis can be challenging when these culture results are negative, requiring specific and often unavailable diagnostic methods. Therefore, a high degree of suspicion of *T. asahii* infection is necessary in patients with risk factors for fungal endocarditis.

Pharmacological treatment is not well established, but voriconazole showed the best results in a case series, although some *T. asahii* subtypes are triazole-resistant. Emergency valve replacement is indicated to improve prognosis in cases of prosthetic valve fungal endocarditis.

The data available in the literature do not allow the standardization of diagnostic methods and pharmacological treatment for *T. asahii* endocarditis, which contributes to the poor prognosis and high mortality rate of this trichosporonosis. In the clinical case reported here, the multiple previous valve replacements added technical difficulty to the new procedure, resulting in an unfavorable outcome. There are no data in the literature on the optimal timing for valve replacement in patients with prior multiple valve replacements.

For these reasons, further studies are required to standardize diagnostic methods and specific antifungal therapies for *T. asahii* endocarditis.

## CONFLICTS OF INTEREST

The author declares that he has no conflicts of interest in this work.

## REFERENCES

1. **Badiee P, Amirghofran AA, Ghazi Nour M, Shafa M, Nemati MH. Incidence and outcome of documented fungal endocarditis. *Int Cardiovasc Res J.* 2014;8(4):152-5.**
2. Pierrotti LC, Baddour LM. Fungal endocarditis, 1995-2000. *Chest.* 2002;122(1):302-10.
3. Rubinstein E, Lang R. Fungal endocarditis. *Eur Heart J.* 1995;16(Suppl B):84-9.
4. Baddour LM, Wilson WR, Bayer AS, Fowler VG Jr, Tleyjeh IM, Rybak MJ et al; on behalf of the American Heart Association Committee on Rheumatic Fever, Endocarditis, and Kawasaki Disease of the Council on Cardiovascular Disease in the Young, Council on Clinical Cardiology, Council on Cardiovascular Surgery and Anesthesia, and Stroke Council. Infective endocarditis in adults: diagnosis, antimicrobial therapy, and management of complications: a scientific statement for healthcare professionals from the American Heart Association. *Circulation.* 2015;132:00-00.
5. Izumi K, Hisata Y, Hazama S. A Rare Case of Infective Endocarditis Complicated by Trichosporon Asahii Fungemia Treated by Surgery. *Ann Thorac Cardiovasc Surg.* 2009;15(5):350-3.
6. **Habib G, Lancellotti P, Antunes MJ, Bongiorno MG, Casalta JP, et al. 2015 ESC Guidelines for the management of infective endocarditis. *European Heart Journal.* 2015;36,3075-3123.**
7. Fagundes Junior AAP, Carvalho RT, Focaccia R, Fernandez JG, Araújo HBN, Strabelli TMV, et al. Trichosporon asahii an emerging etiologic agent of fungal infection and colonization in heart failure patients in intensive care unit. Case report and literature review. *Rev. bras. ter. intensiva.* 2008; 20(1):106-9.
8. **de Almeida Júnior JN, Hennequin C. Invasive Trichosporon Infection: a Systematic Review on a Re-emerging Fungal Pathogen. *Front Microbiol.* 2016;7:1629.**
9. Colombo AL, Padovan AC, Chaves GM. Current knowledge of Trichosporon spp. and Trichosporonosis. *Clin Microbiol Rev.* 2011;24(4):682-700.
10. Wolf DG, Falk R, Hacham M, Theelen B, Boekhout T, Scorzetti G et al. Multidrug-resistant Trichosporon asahii infection of non-granulocytopenic patients in three intensive care units. *J Clin Microbiol.* 2001;39:4 420-5.
11. Ramos JM, Cuenca-Estrella M, Gutierrez F, Elia M, Rodriguez-Tudela JL. Clinical case of endocarditis due to Trichosporon inkin and antifungal susceptibility profile of the organism. *J Clin Microbiol.* 2004;42:2341-4.
12. Goiti J, Gallo I. Cirugía de la endocarditis valvular activa. *Rev Esp Cardiol.* 2001;54:259-260.